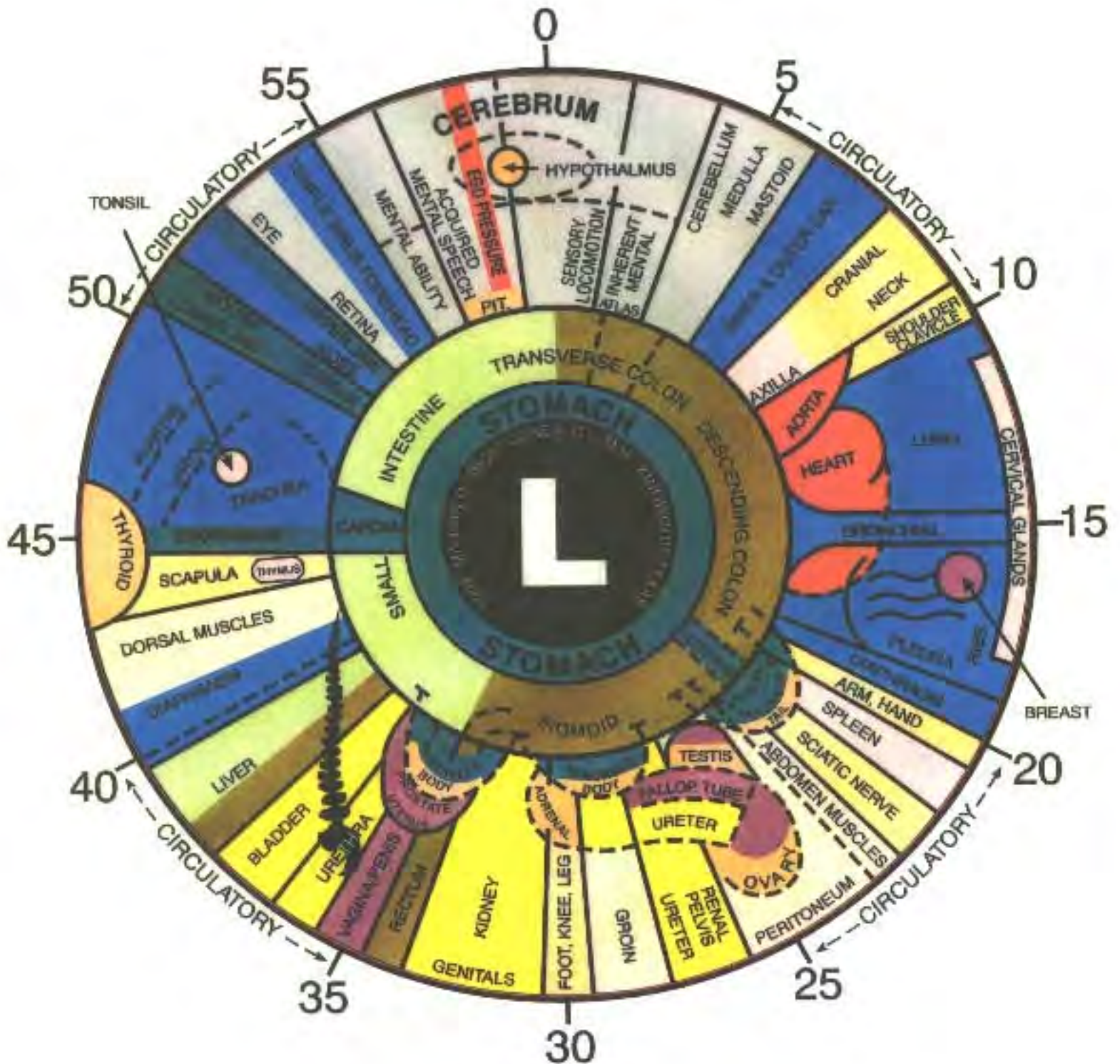


LEFT IRIS



| CHAKRA & COLOUR | ASSOCIATED BODY PARTS | BALANCED ENERGY CHARACTERISTICS | EXCESSIVE CHAKRA ENERGY | DEFICIENT CHAKRA ENERGY | MALFUNCTION at PHYSICAL LEVEL. |
|---|---|---|---|---|--|
| First Chakra RED Base of spine | Spine, legs, teeth bones, nails, feet rectum, colon, Intestines, blood. | Centred, healthy, lively, affectionate, trusting, energetic, spiritual. | Egotistic, greedy, materialistic, domineering. | Lack confidence, weak, spacey, unfocused, and suicidal. | Obesity, constipation, arthritis, knee problems, Low stamina. |
| Second Chakra ORANGE Sacral | womb, kidneys, bladder, pelvic, lymph, Gastric juices. | Friendly, optimistic, creative, intuitive, sense of humour. | Aggressive, manipulative, overly ambitious, delusive. | Shy, timid, sensitive, fearful, resentful, frigid, passive. | Impotence, uterus problems, bladder, kidneys, Lower back pain. |
| Third Chakra YELLOW Solar Plexus | Lower back, abdomen, liver, spleen, and digestive & nerve system. | Outgoing, cheerful, relaxed, skilful, warm, and intelligent. | Judgmental, workaholic, perfectionist, Hyperactive. | Depressed, confused, insecure, and jealous. | Ulcers, diabetes, nervousness, bulimia, anorexia. |
| Fourth Chakra GREEN Heart | Heart, lungs, arms, hands, upper back, circulation, skin. | Compassionate, balanced, humanitarian. | Demanding, critical, possessive, Moody, controlling. | Paranoid, indecisive, unloved, fearful, worried. | Asthma, high blood pressure, lung disease, heart disease. |
| Fifth Chakra BLUE Throat | Neck, shoulders, jaw, ears, bronchial tubes. | Contented, good speaker, meditative, inspired. | Arrogant, talks too much, addictive, Self-righteous. | Scared, timid, quiet, weak, and inconsistent. | Sore throat, stiff neck, colds, thyroid, hearing problems. |
| Sixth Chakra INDIGO Third eye (Brow) | Eye, two hemispheres of the brain, sinuses, face. | Charismatic, receiver of guidance spiritually enlightened. | Proud, egotistic, manipulative, authoritarian. | Undisciplined, oversensitive, afraid of success. | Headaches, visual disturbances, nightmares. |
| Seventh Chakra WHITE Crown | Cortex, central nervous system. | Miracle worker, In touch with nature. | Psychotic, frustrated, destructive, depressed. | No spark of joy, can't make decisions. | Migraines, depression, alienation, inability to learn. |

Small
Intest.

Brain
Areas

Colon

Nose

Neck

Larynx

Lungs

L

Heart

Thyroid

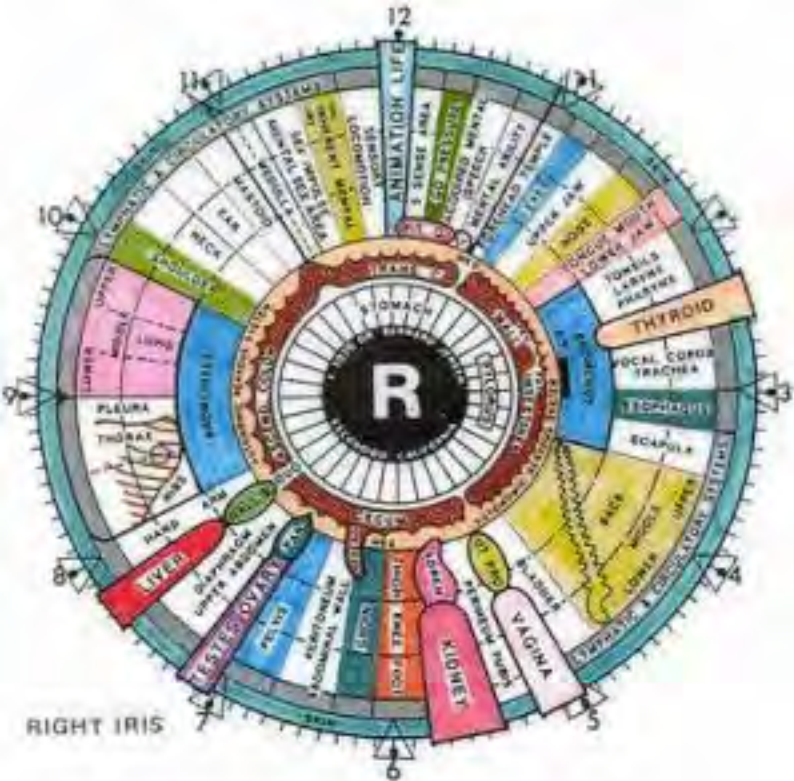
Spleen

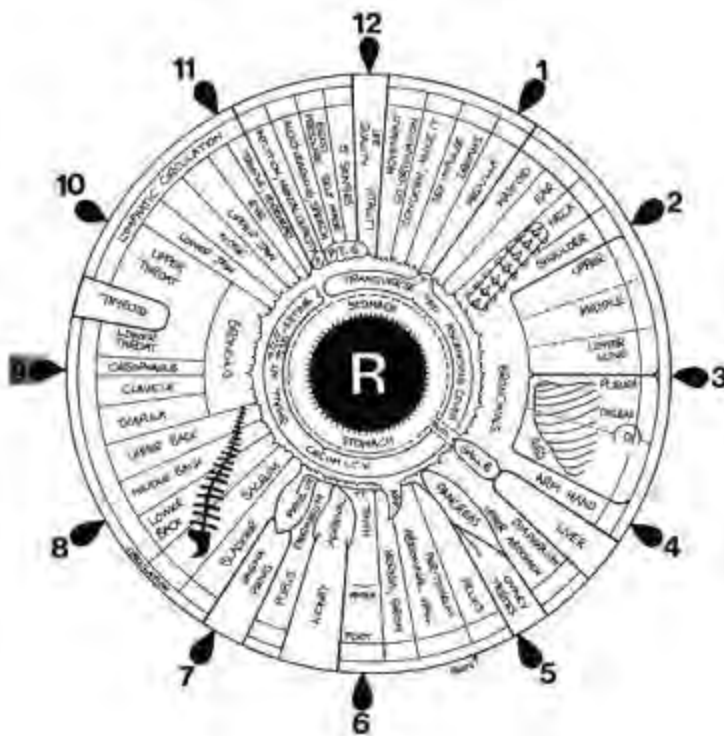
Spine

Bladder

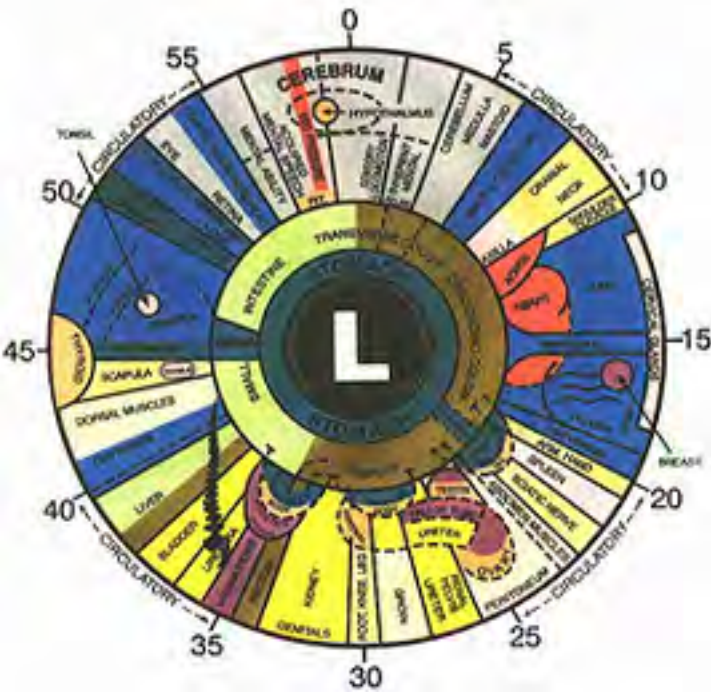
Ovary

Kidney



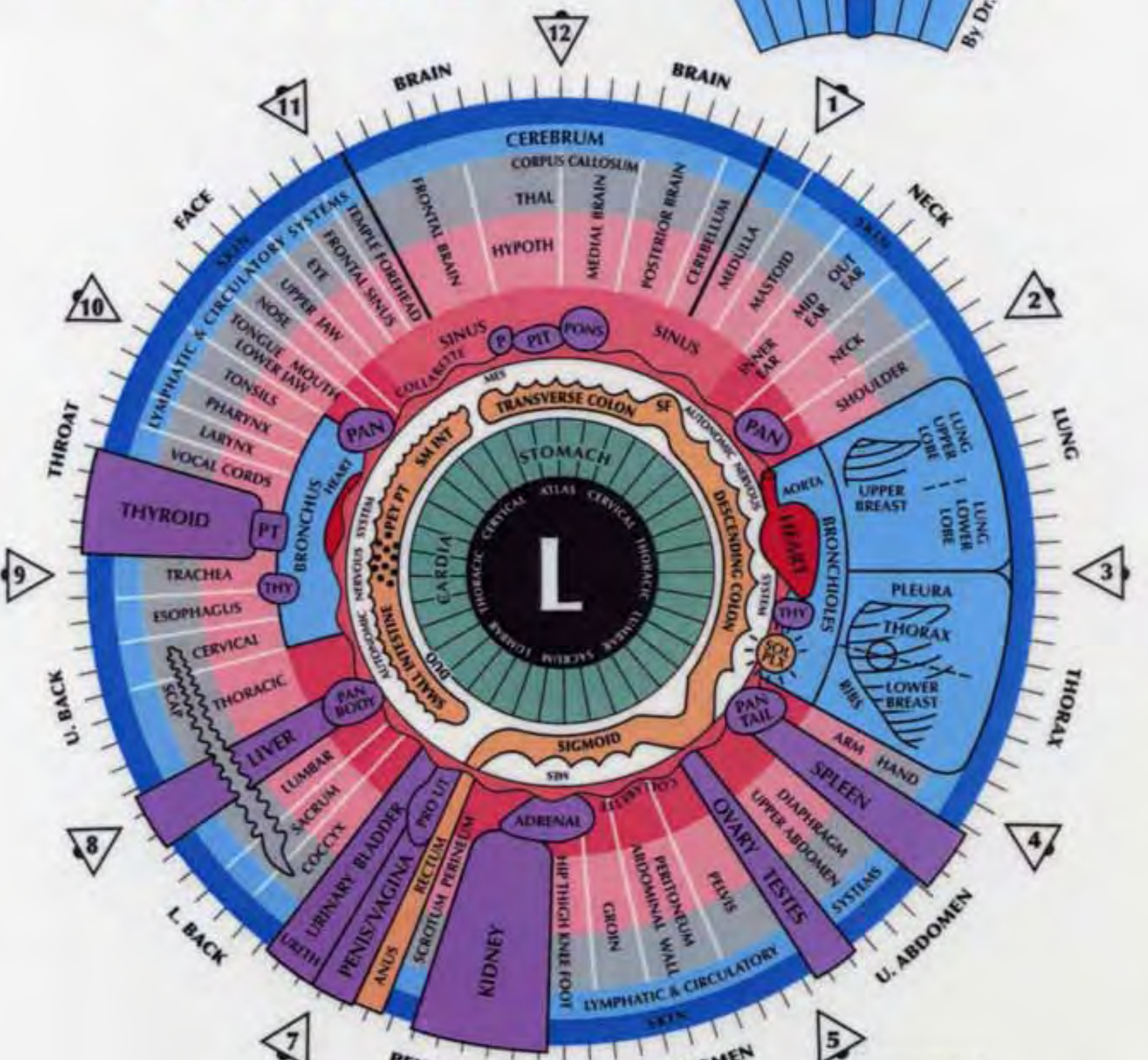
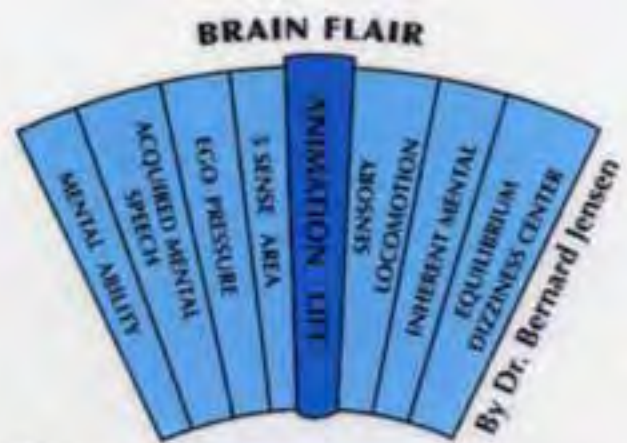


LEFT IRIS





IRIDODOLOGY CHART

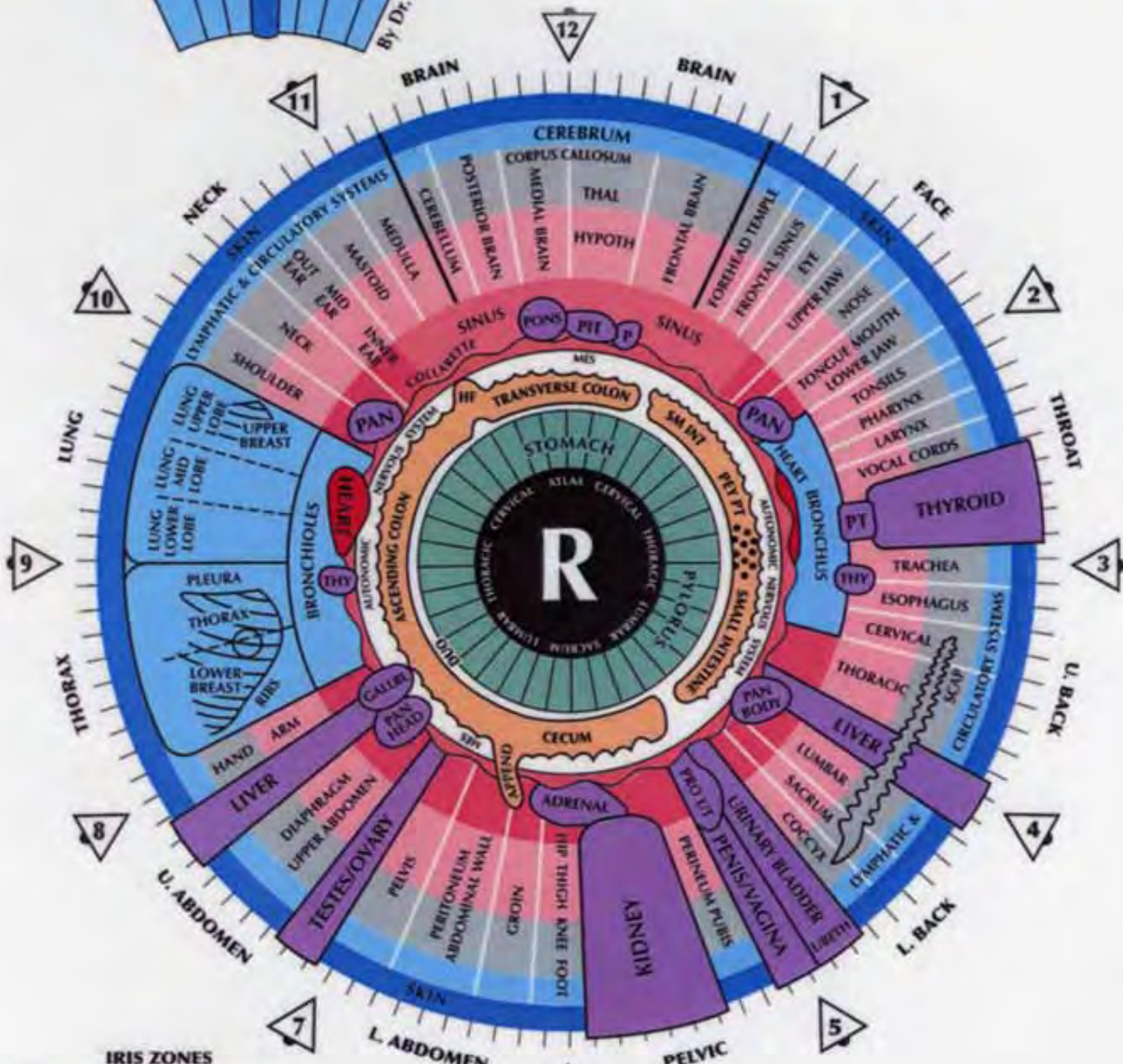
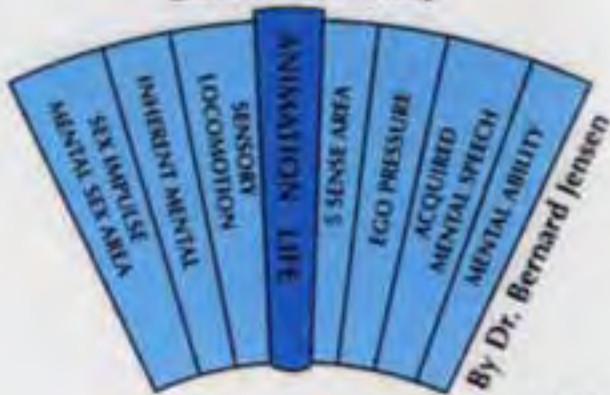

ABBREVIATIONS

| | | | |
|--------|-----------------|---------|------------------|
| APPEND | Appendix | PEY PT | Peyers Patches |
| DUO | Duodenum | PIT | Pituitary |
| GALLBL | Gallbladder | PRO | Prostate |
| HF | Hepatic Flexure | SF | Spleenic Flexure |
| HYPOTH | Hypothalamus | SCAP | Scapula |
| MES | Mesentery | SOL PLX | Solar Plexus |
| P | Pineal | THAL | Thalamus |
| PT | Parathyroid | THY | Thymus |
| PAN | Pancreas | URETH | Urethra |

IRIDOLOGY CHART

BRAIN FLAIR



IRIS ZONES

- STOMACH - NUTRITIVE ZONE
 - INTESTINES - NUTRITIVE ZONE
 - BLOOD & LYMPH - HUMORAL ZONE
 - MUSCULATURE
 - BONY STRUCTURE
 - SUPERFICIAL LYMPH & BLOOD
 - SKIN & ORIFICES
- } CILIARY ZONE

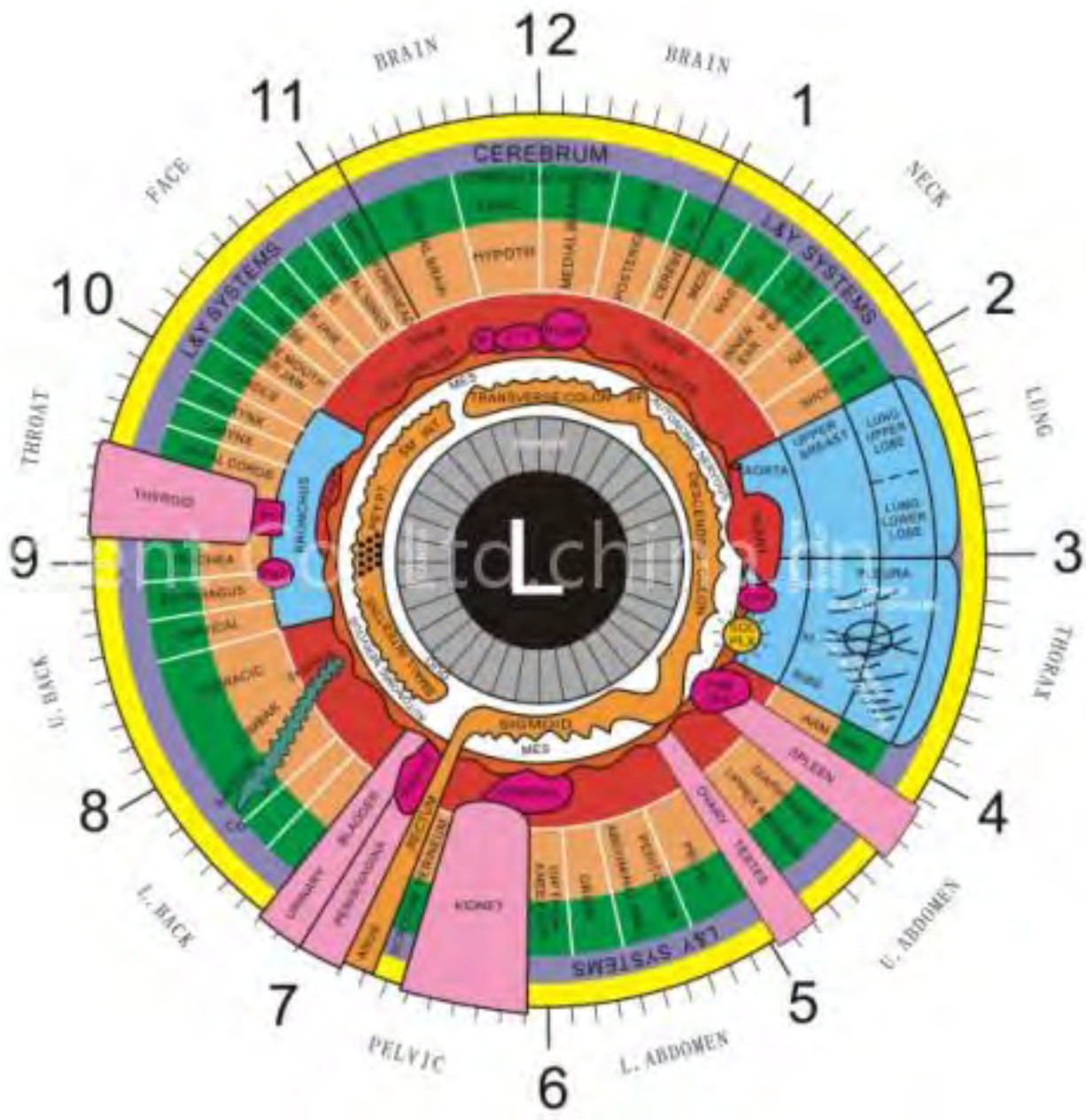
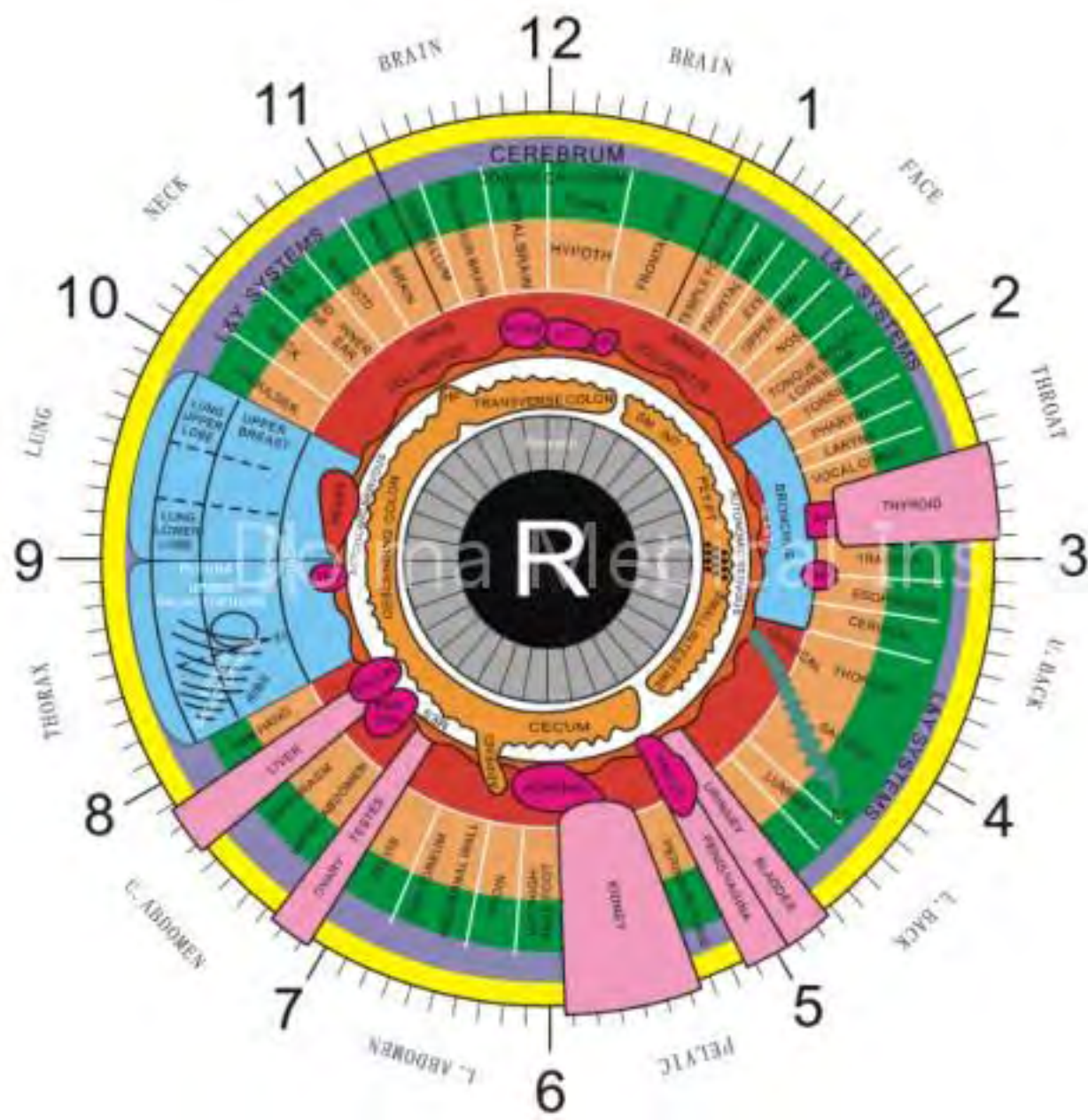
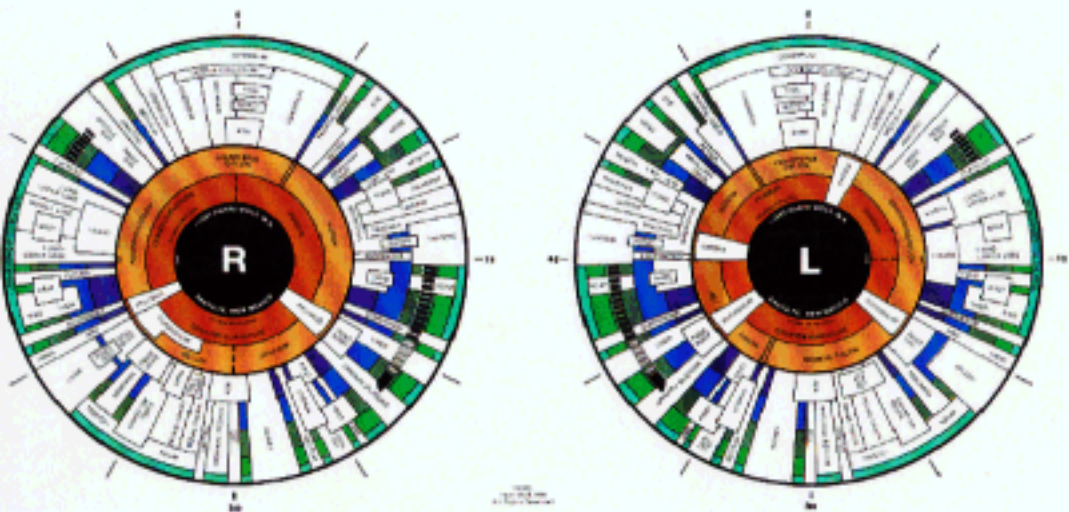


CHART OF APPLIED IRIDOLOGY™



Developed by
Harri Wolf, M.A.

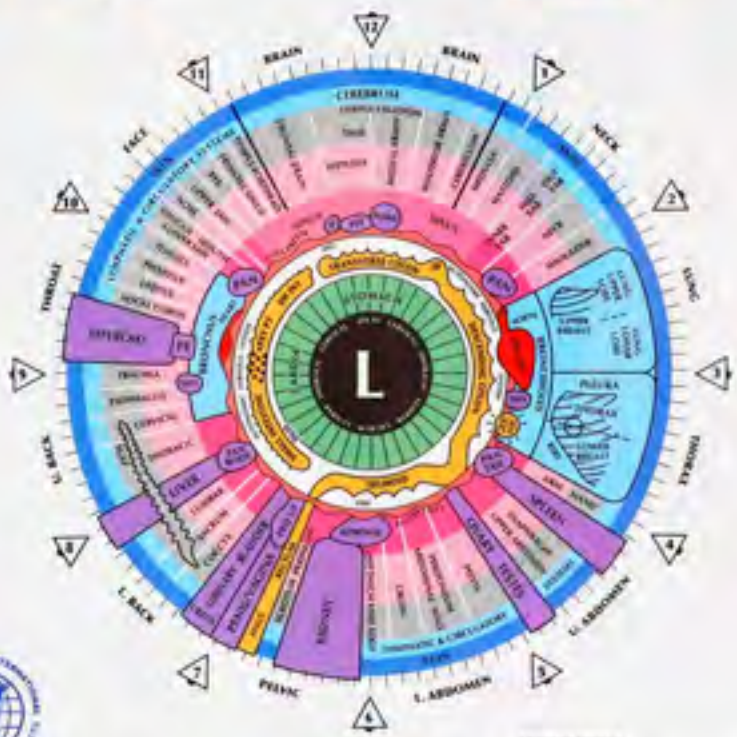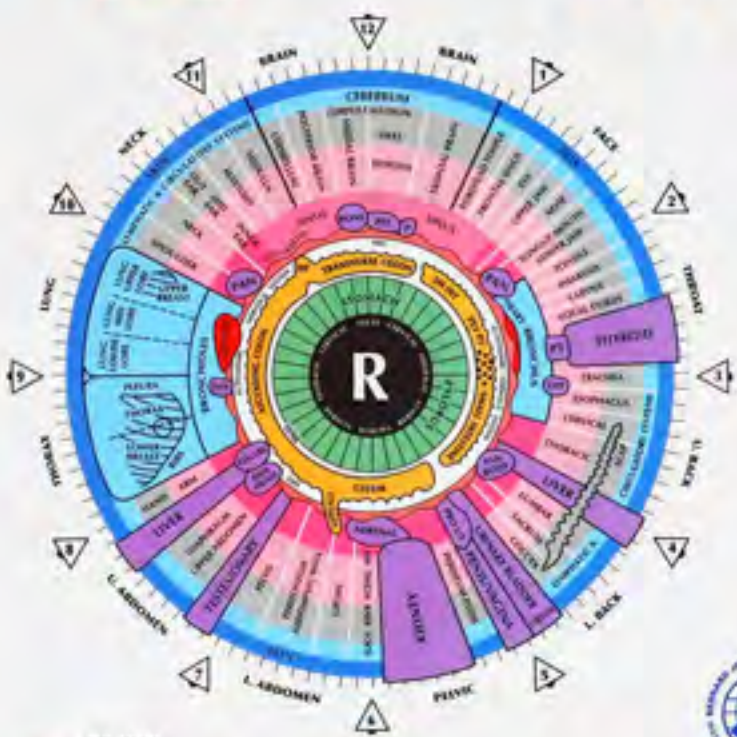
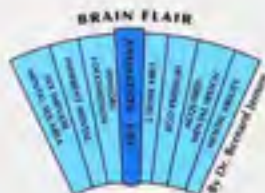Author, *Applied Iridology Research and Clinical Practice*, New York

INNER ZONATIONAL SYSTEM

- INNER ZONE
- ORANGE
- MIDDLE ZONE
- BLUE
- GREEN
- WHITE
- OUTER ZONE
- GREEN
- BLUE
- WHITE

Copyright © 1995 by Harri Wolf, M.A.
All rights reserved.
Printed in the United States of America

IRIDODOLOGY CHART



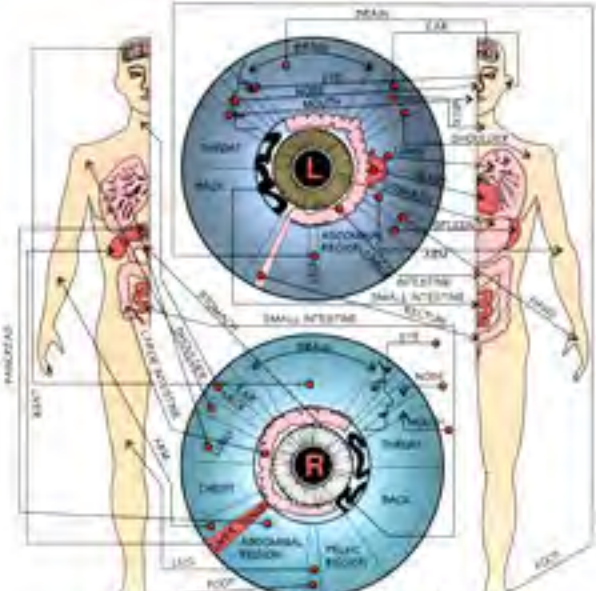
- IRIS ZONES**
- STOMACH - NUTRITIVE ZONE
 - INTESTINES - NUTRITIVE ZONE
 - BLOOD & Lymph - HUMERAL ZONE
 - MUSCULATURE
 - BONY STRUCTURE
 - SUPERFICIAL Lymph & BLOOD
 - SKIN & ORGANS
- CLAYTON ZONE**



Developed by Bernard Jensen, D.C., Ph.D.
 with revisions by Ellen Jensen, Ph.D., D.Sc.
 © 2004
 Phone # 760-291-1255
www.bernardjensen.org

ABBREVIATIONS

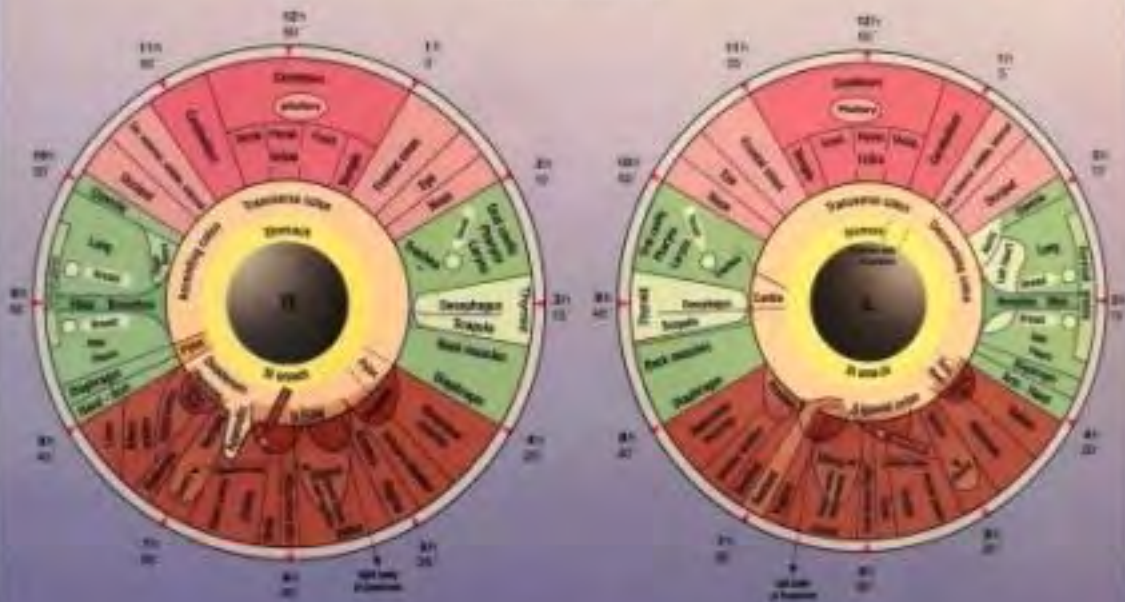| | | | |
|--------|--------------|---------|-----------------|
| APPEND | Appendix | PEY PT | Peyer's Patches |
| BLVD | Colon | PI | Pinna |
| CALLBL | Callus | PRD | Prostate |
| HE | Hepatic Duct | SI | Sigmoid Flexure |
| HYPOTH | Hypothalamus | SCAP | Scapula |
| MES | Mesentery | SOL PLX | Solar Plexus |
| P | Pituitary | THAL | Thalamus |
| PT | Pituitary | THY | Thyroid |
| PAN | Pancreas | URETH | Urethra |



THE LEFT ILLS REFERS TO THE LEFT SIDE OF THE BODY.
 THE RIGHT ILLS REFERS TO THE RIGHT SIDE OF THE BODY.

TOPOGRAPHIC OVERVIEW OF THE IRIS

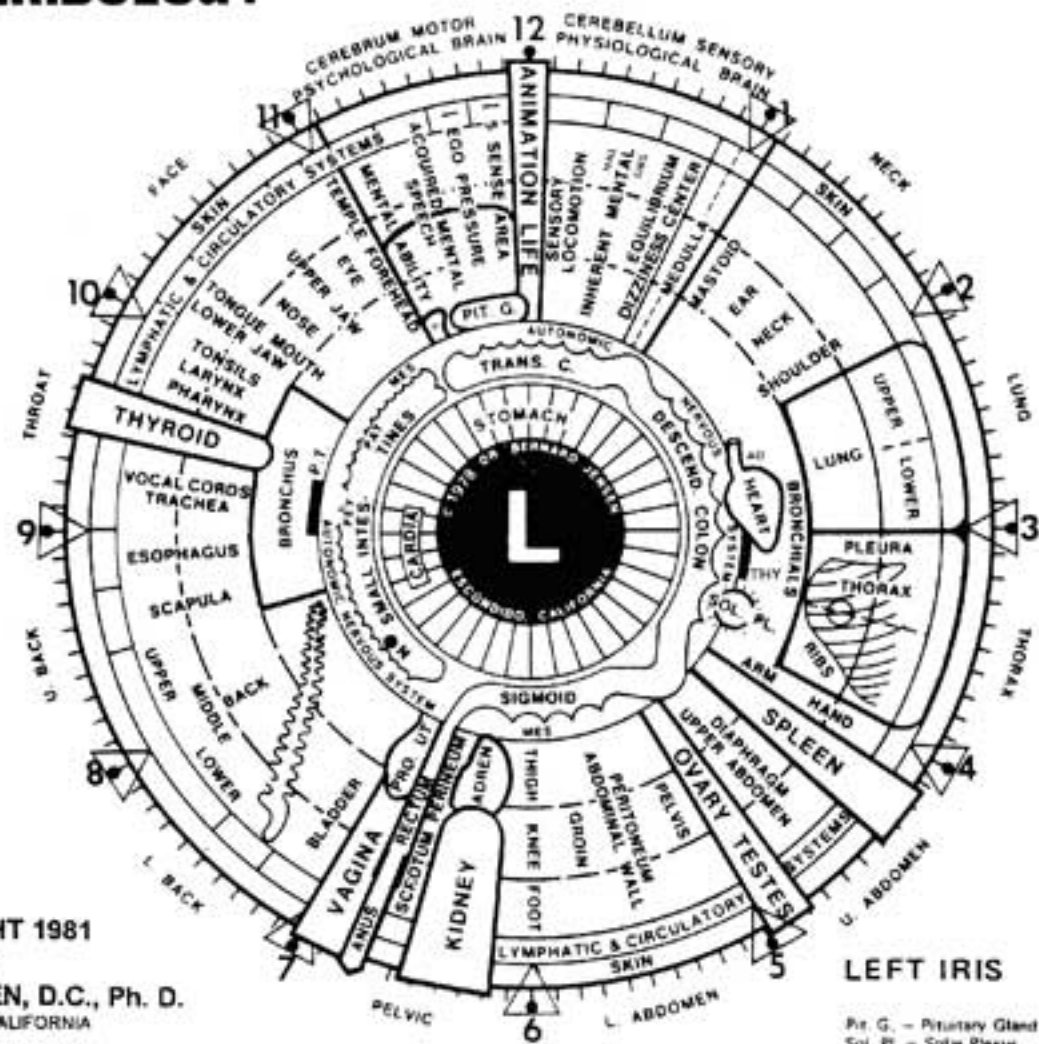
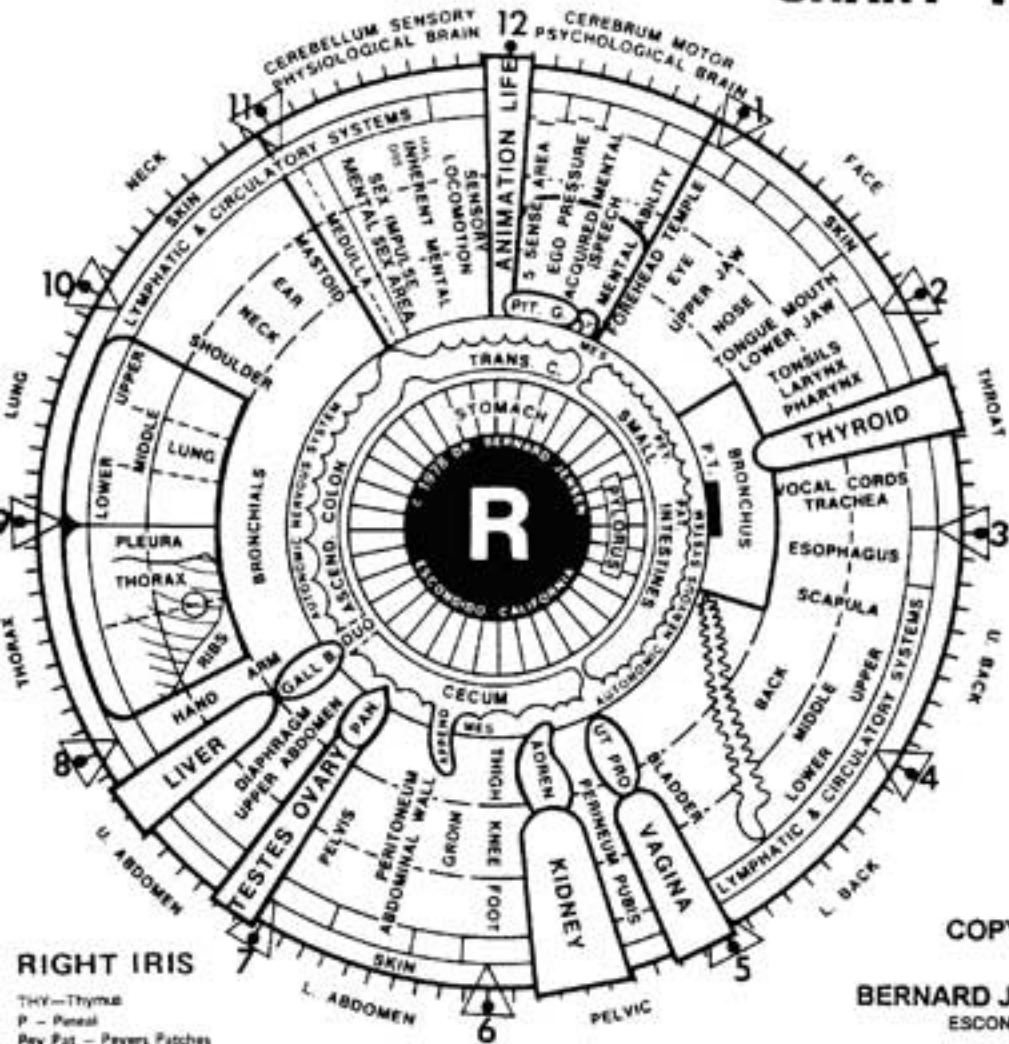
BASED ON JOSEF DECK



© 2000 Paliss Institut • Heilstrasse 2 • D-71284 Hornstaad • All Rights reserved

Reproduction of this diagram is permitted for personal use only. All other rights reserved. For more information, please contact the Paliss Institut, Heilstrasse 2, D-71284 Hornstaad, Germany. Tel: +49 7142 9000-0. Fax: +49 7142 9000-1. Email: info@paliss-institut.de

CHART TO IRIDODOLOGY



COPYRIGHT 1981

BY

BERNARD JENSEN, D.C., Ph. D.

ESCONDIDO, CALIFORNIA

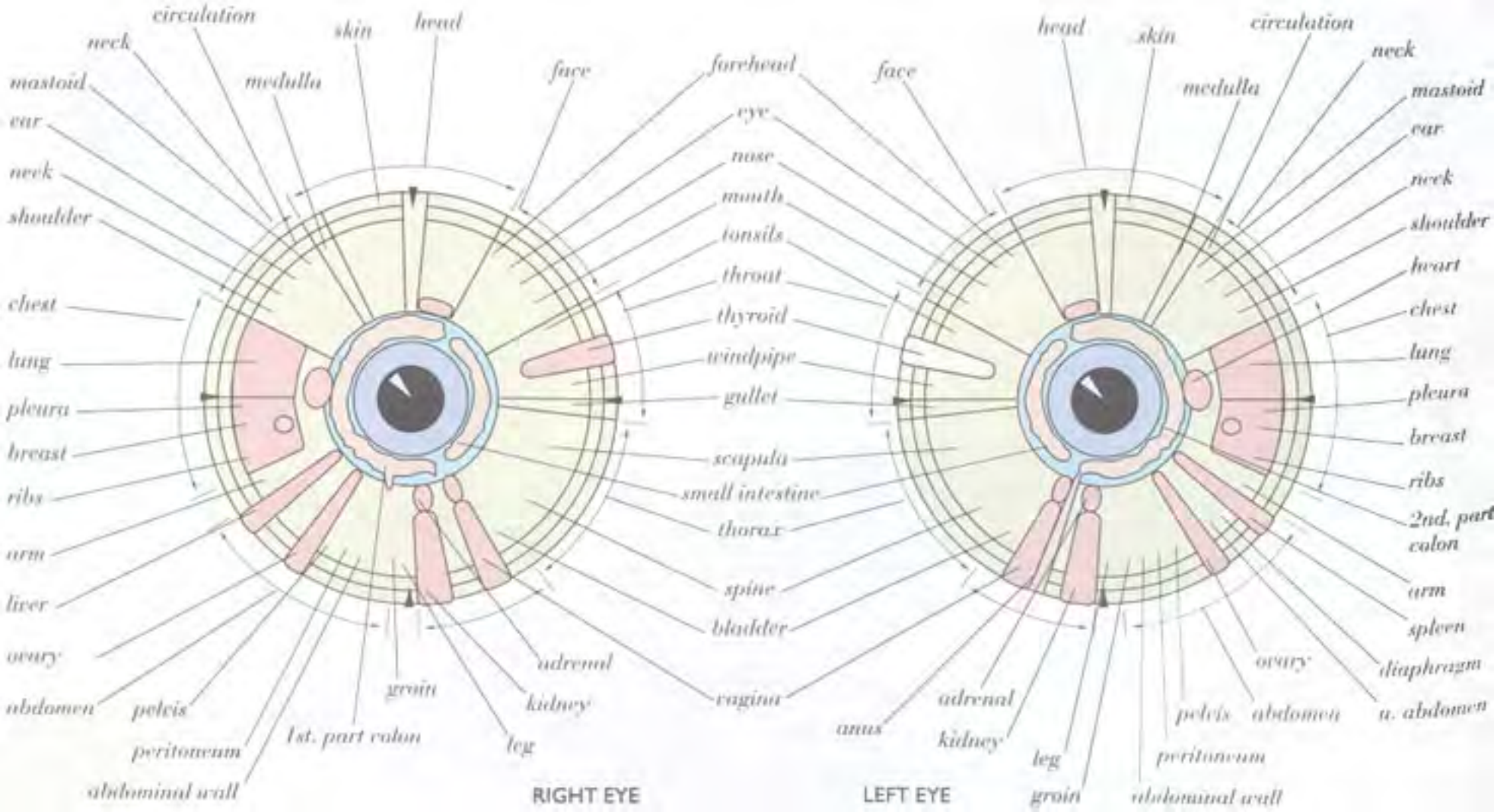
IRIDODOLOGY CHART developed by Bernard Jensen, D.C., Ph.D.

RIGHT IRIS

Thy - Thyroid
P - Pituitary
P.F. - Peyer's Patches
Mes - Mesentery
Hal - Hallucination
P.T. - Para Thyroid

LEFT IRIS

Pit. G. - Pituitary Gland
Sol. Pl. - Solar Plexus
N - Navel
Obs - Obsession
AO - Aorta



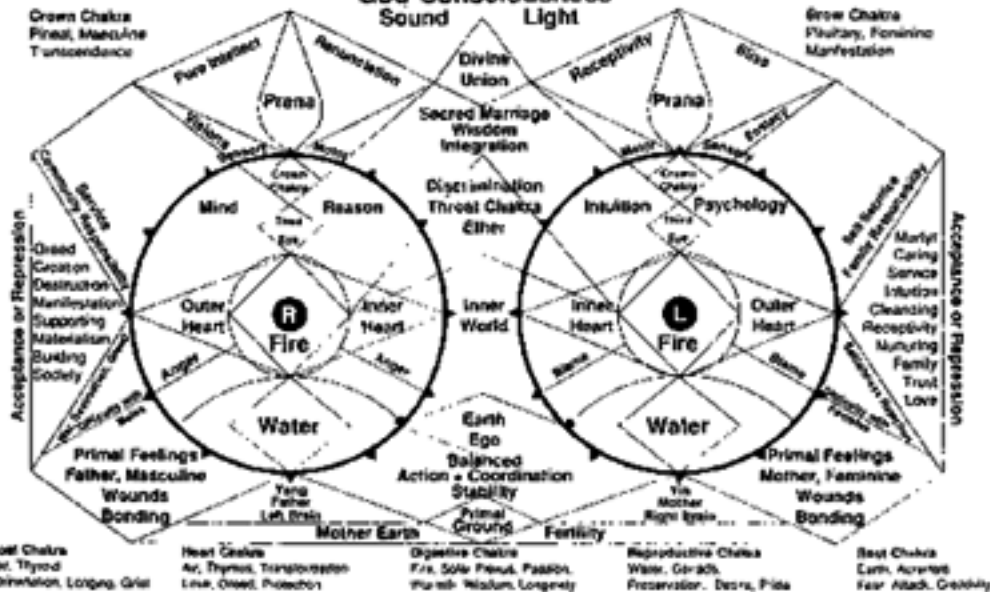RIGHT EYE

LEFT EYE

Iridology, Chakras, Elements and Emotions

© Farda Sharan

God Consciousness Sound Light



Throat Chakra
Brain, Thyroid
Discrimination, Lungs, Gland

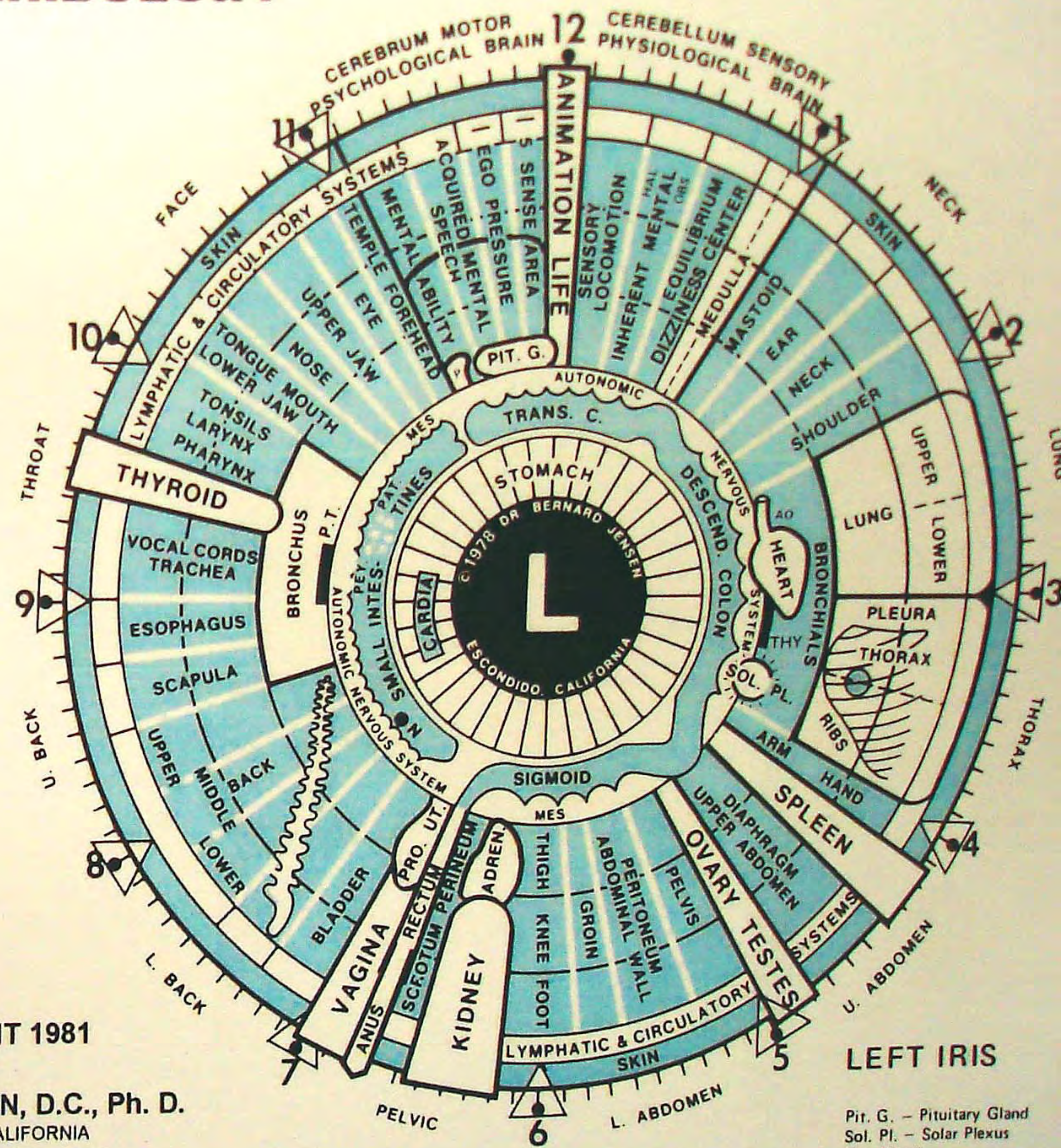
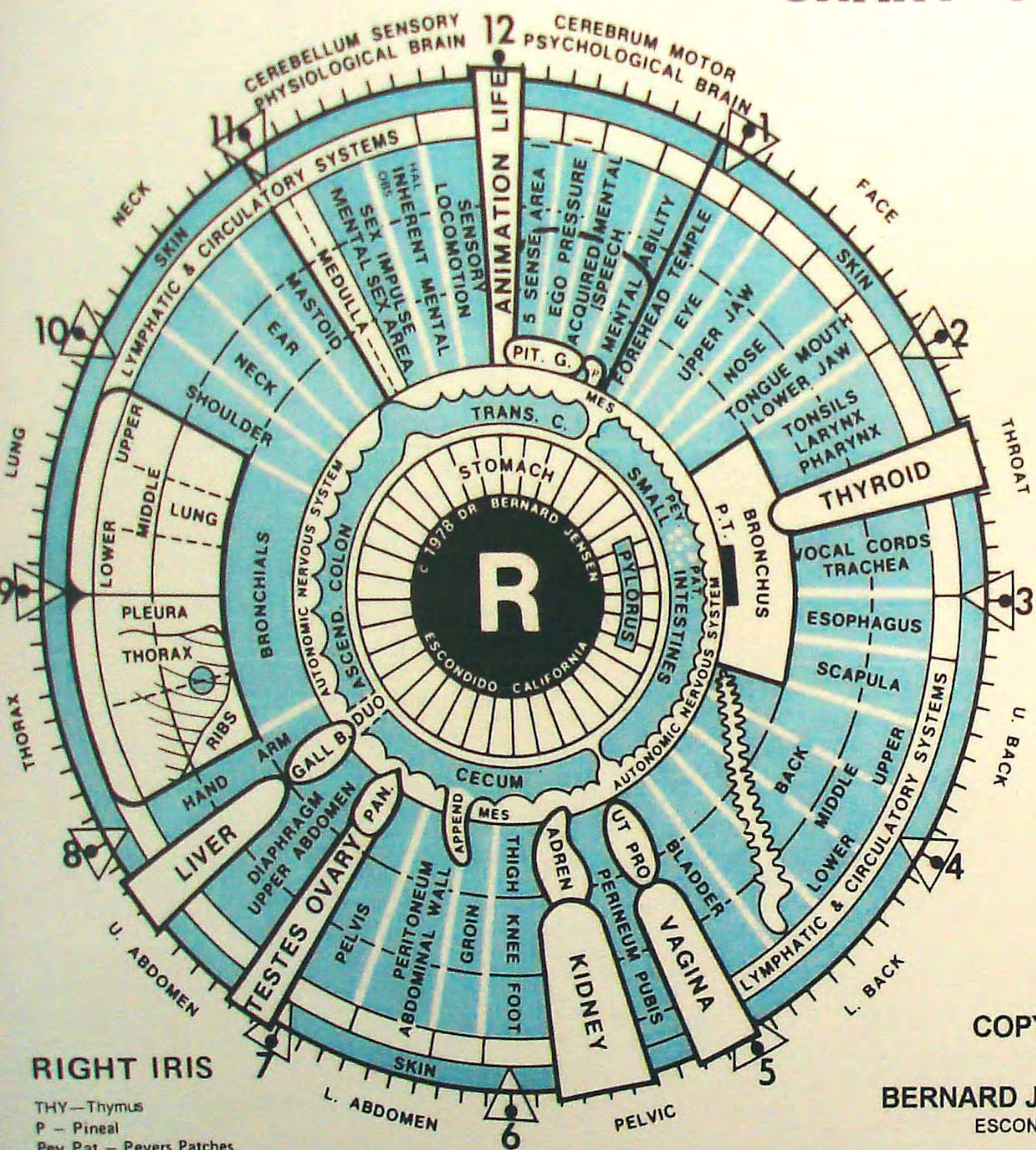
Heart Chakra
Ar, Thyroid, Translocation
Liver, Oment, Pleuroch

Digestive Chakra
Es, Solar Plexus, Passion,
Marsh, Wisdom, Longevity

Reproductive Chakra
Womb, Ovaries,
Preservator, Decays, Piles

Root Chakra
Earth, Anus,
Feet, Atank, Goidity

CHART TO IRIDOLOGY



RIGHT IRIS
 THY—Thymus
 P—Pineal
 Pey Pat—Peyers Patches
 Mes—Mesentery
 Hal—Hallucination
 P.T.—Para Thyroid

COPYRIGHT 1981
 BY
BERNARD JENSEN, D.C., Ph. D.
 ESCONDIDO, CALIFORNIA

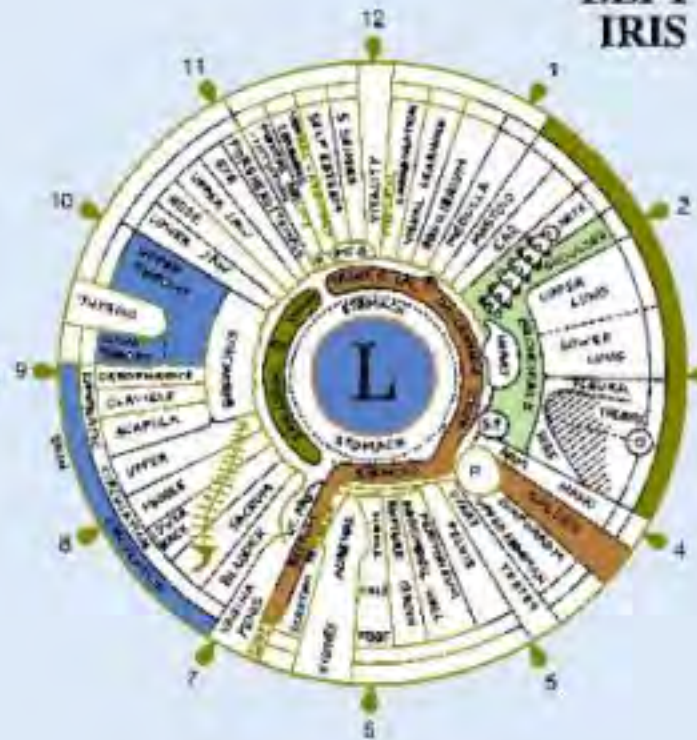LEFT IRIS
 Pit. G.—Pituitary Gland
 Sol. Pl.—Solar Plexus
 N—Naval
 Obs—Obsession
 AO—Aorta

IRIDOLOGY CHART developed by Bernard Jensen, D.C., Ph.D.

RIGHT IRIS



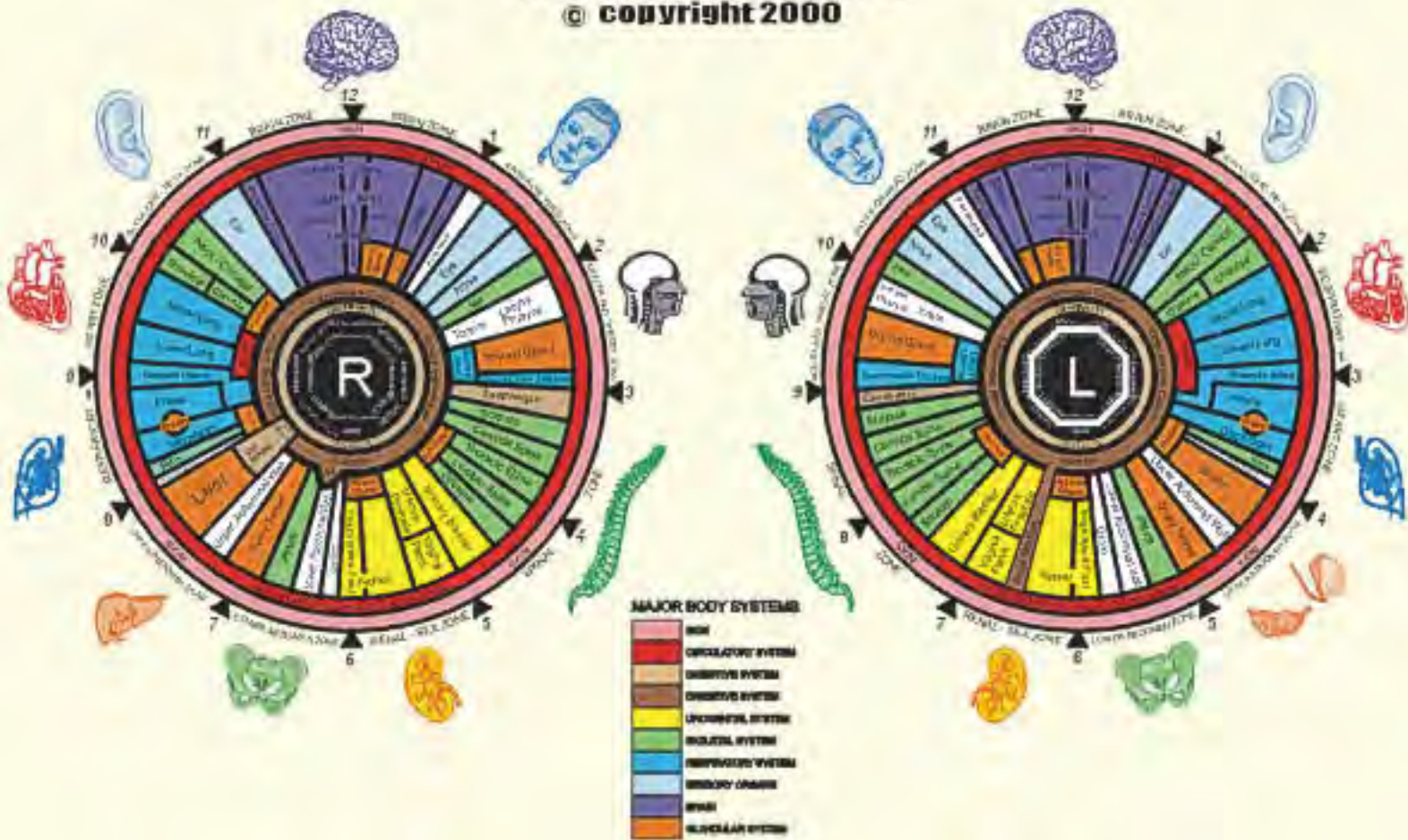
LEFT IRIS

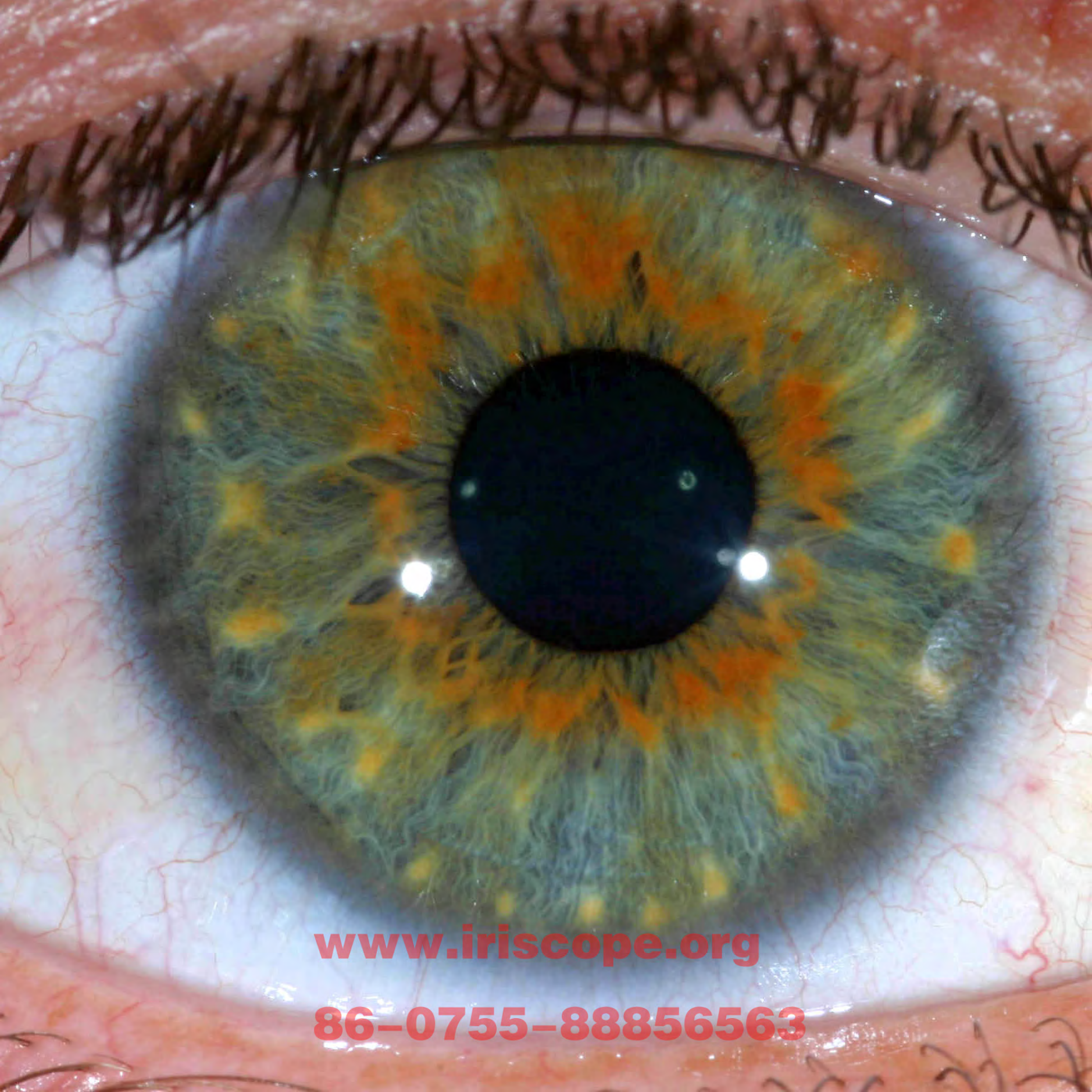

IRIDOLGY CHART

ACCORDING TO
FRANK NAVRATIL BSc. N. D.

© copyright 2000





www.iriscscope.org

86-0755-88856563

Adjacent sclera
neoplasm indicator



Lung

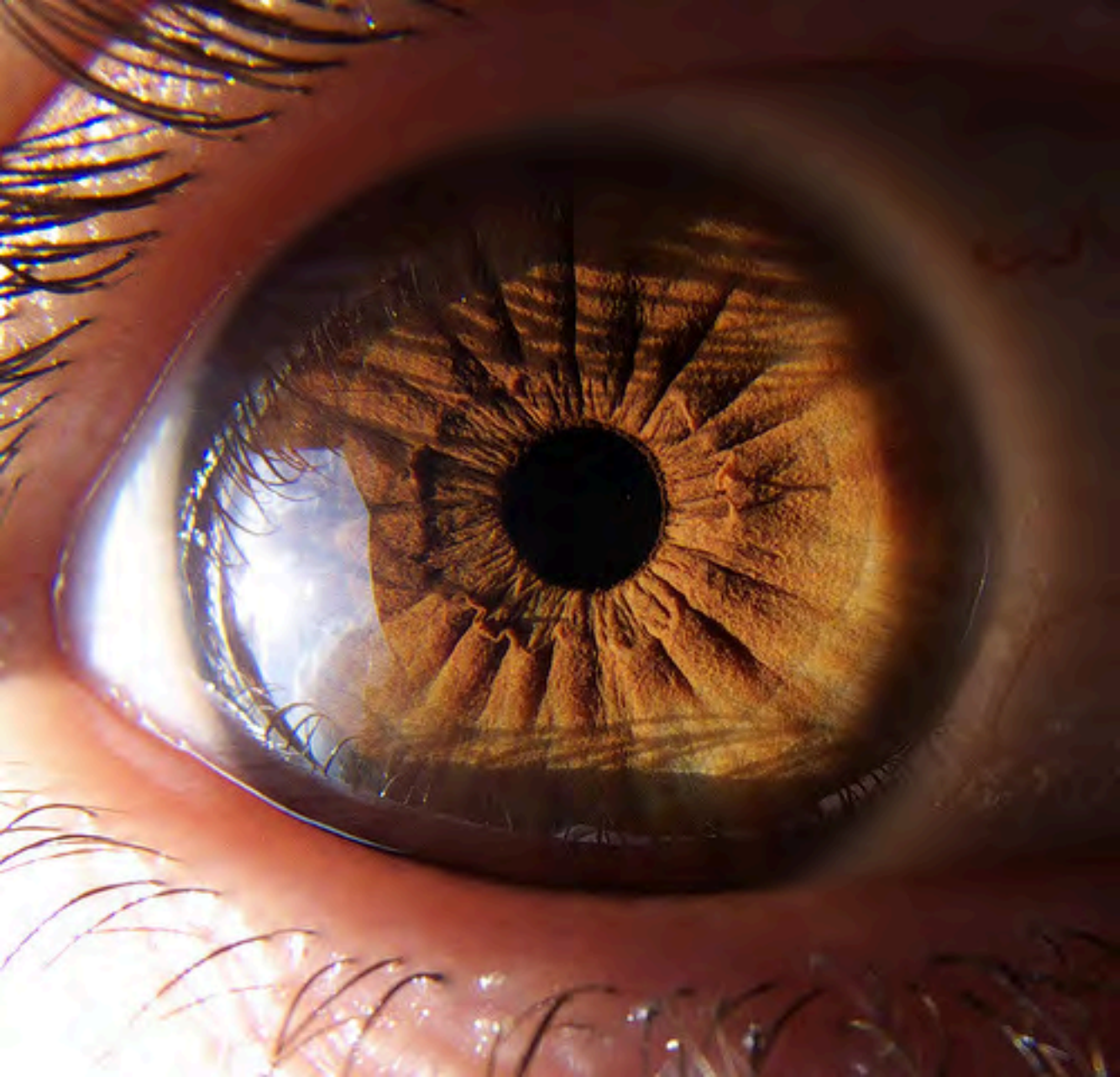

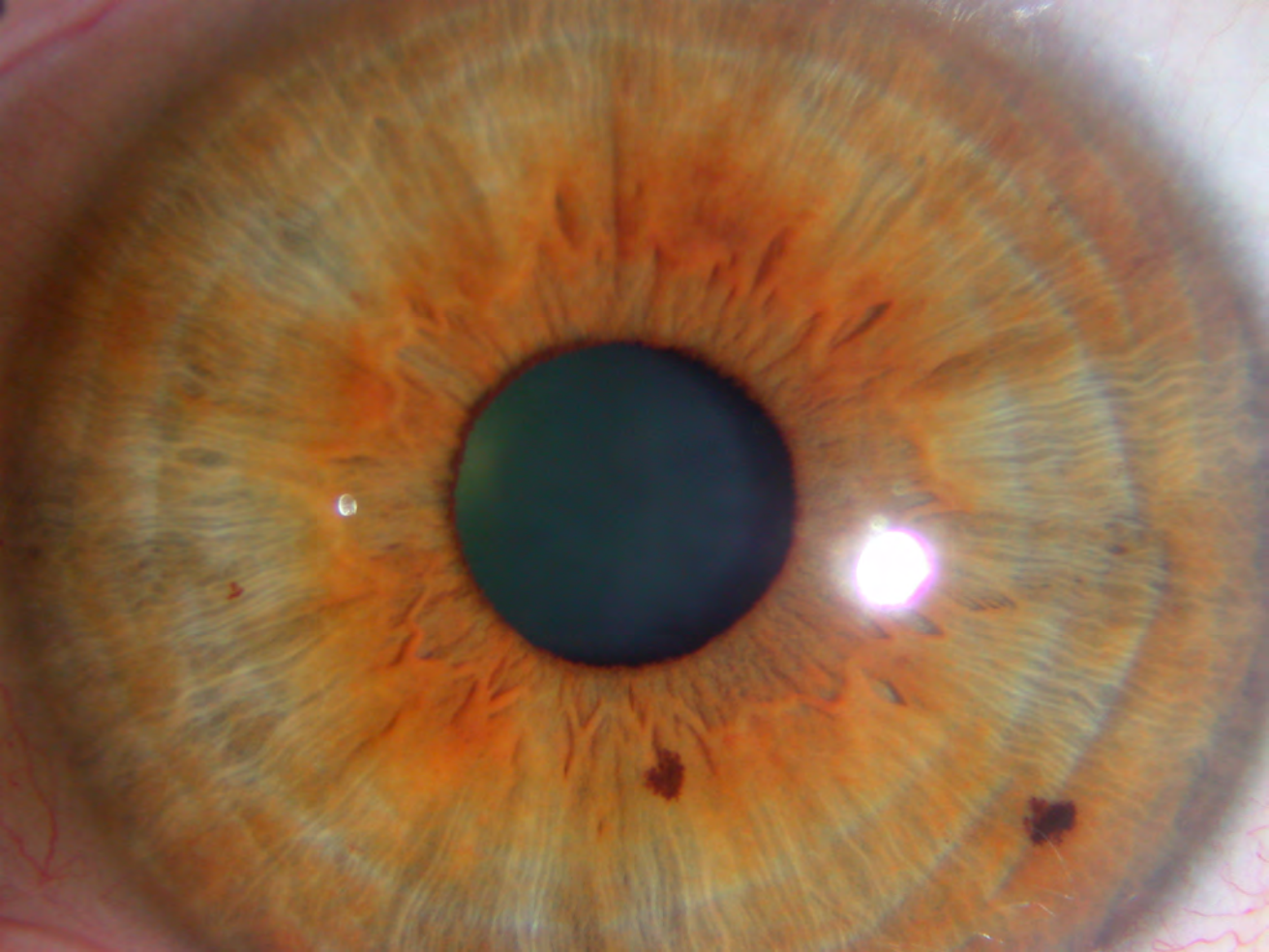
Black pigment
(neoplasm marker)

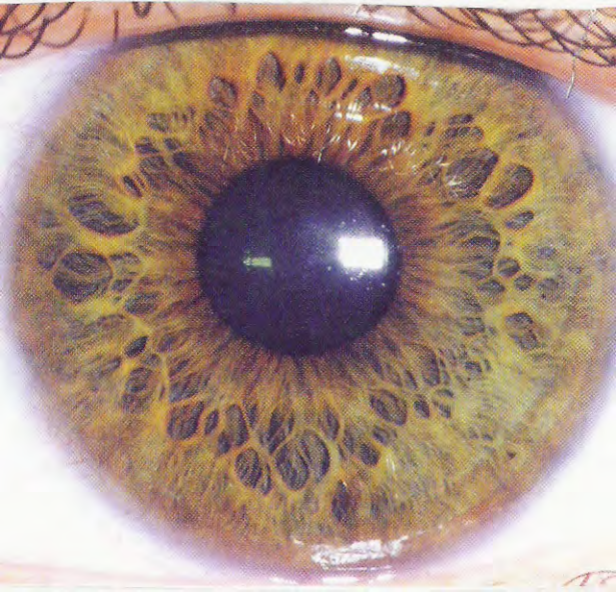


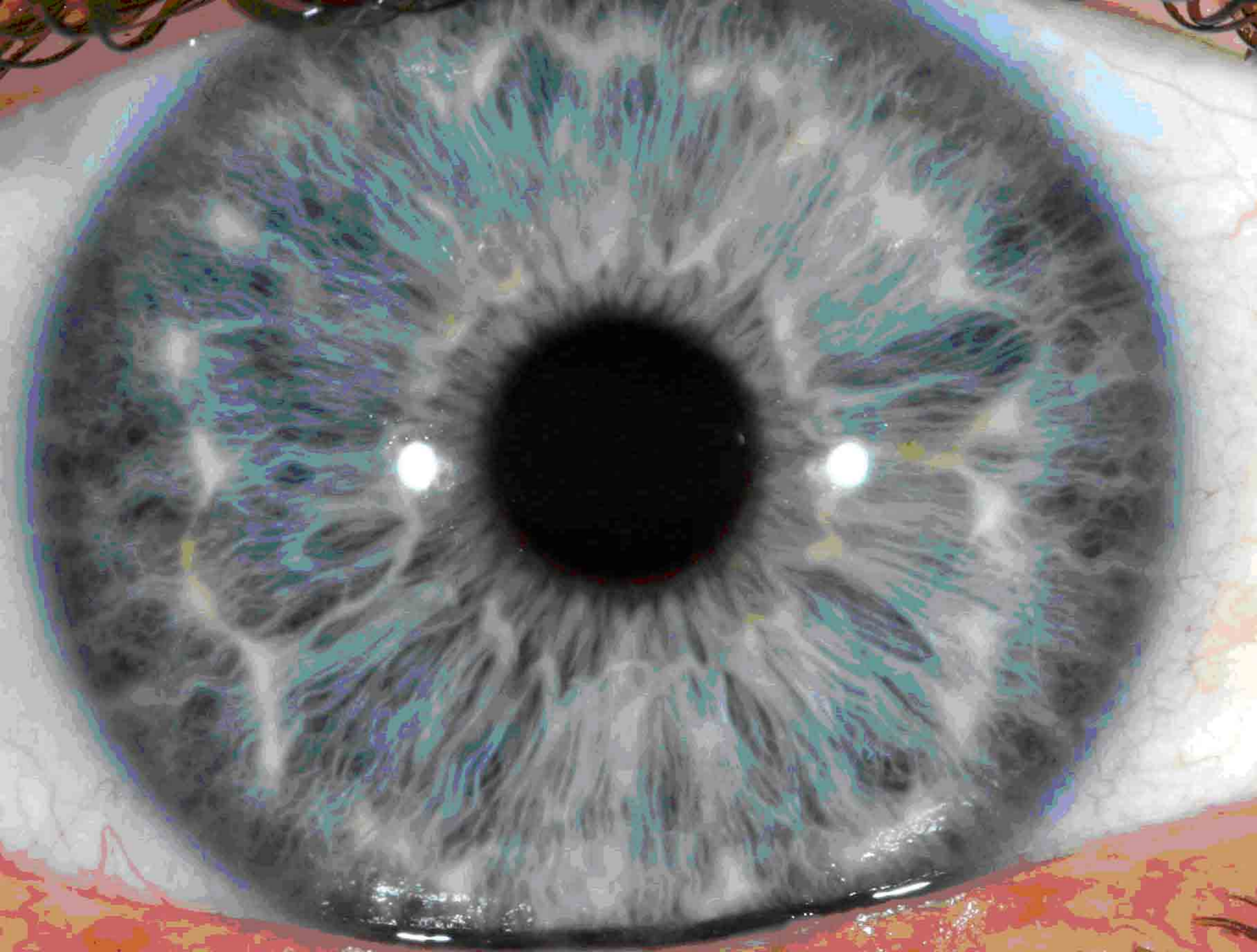
LOCY/IRISCOPE

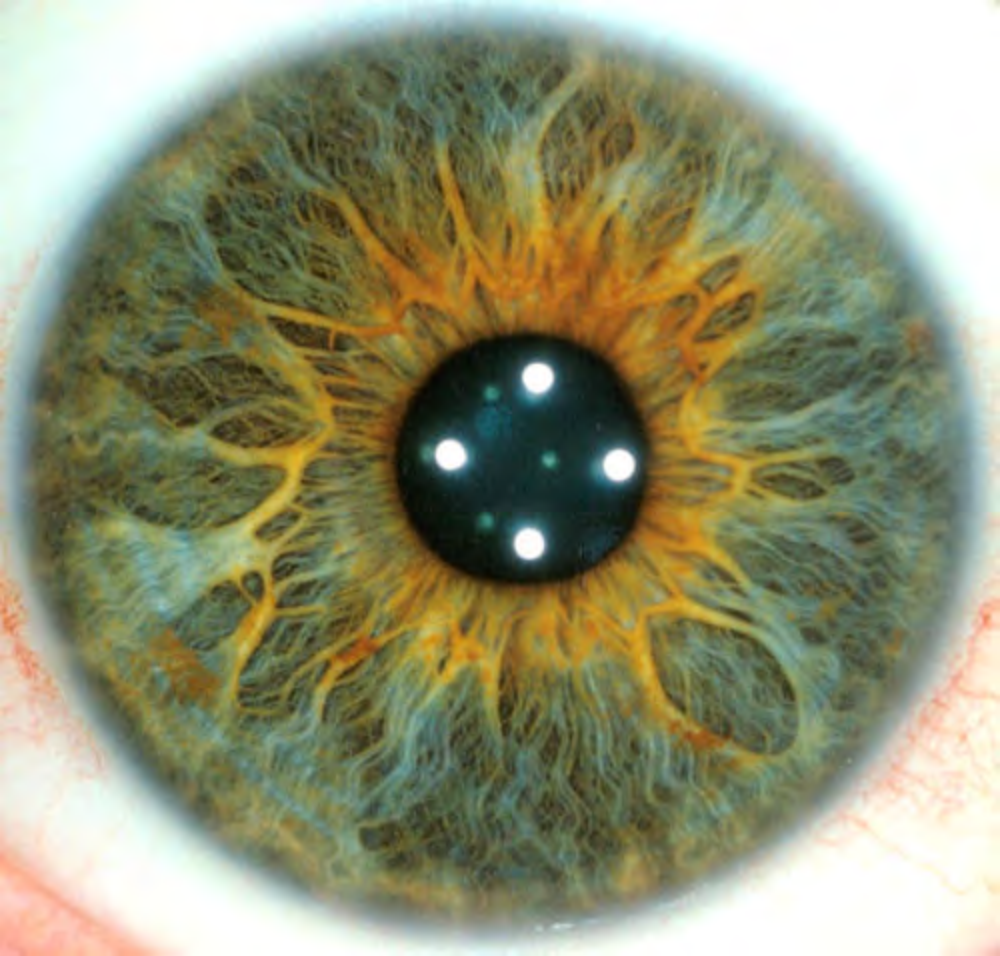


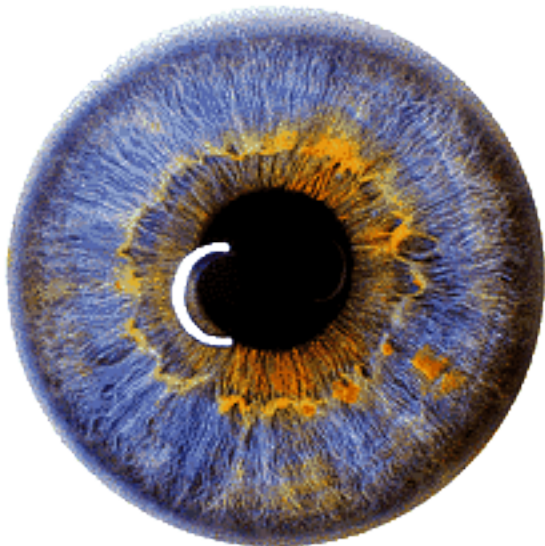








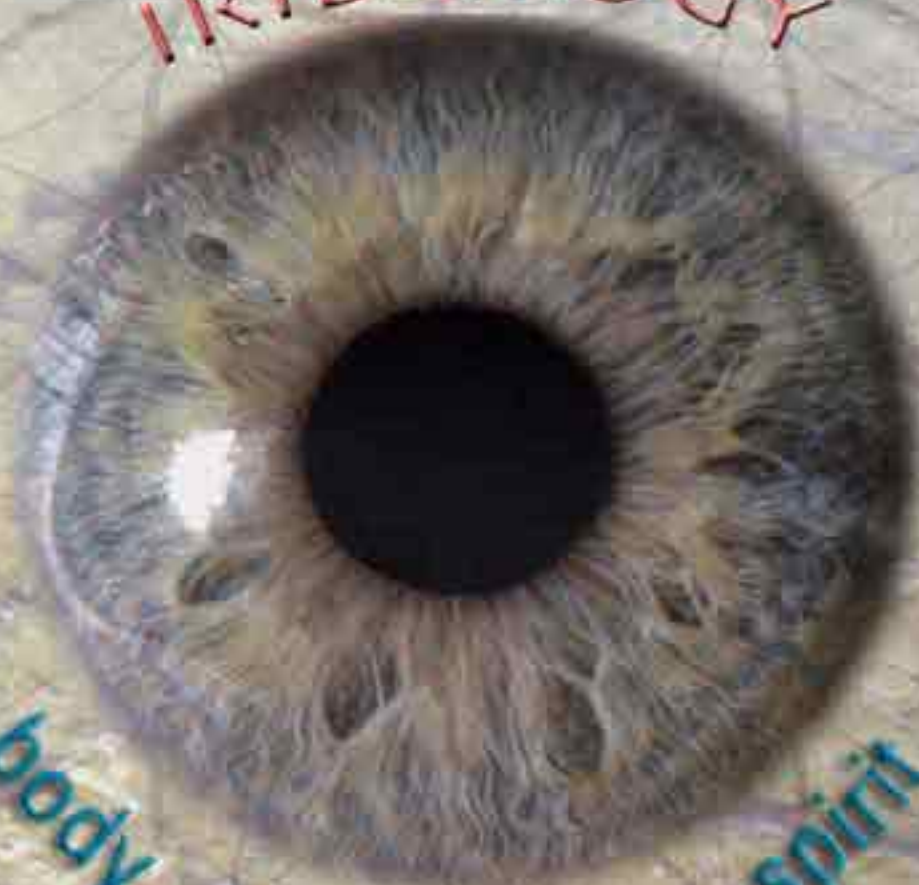


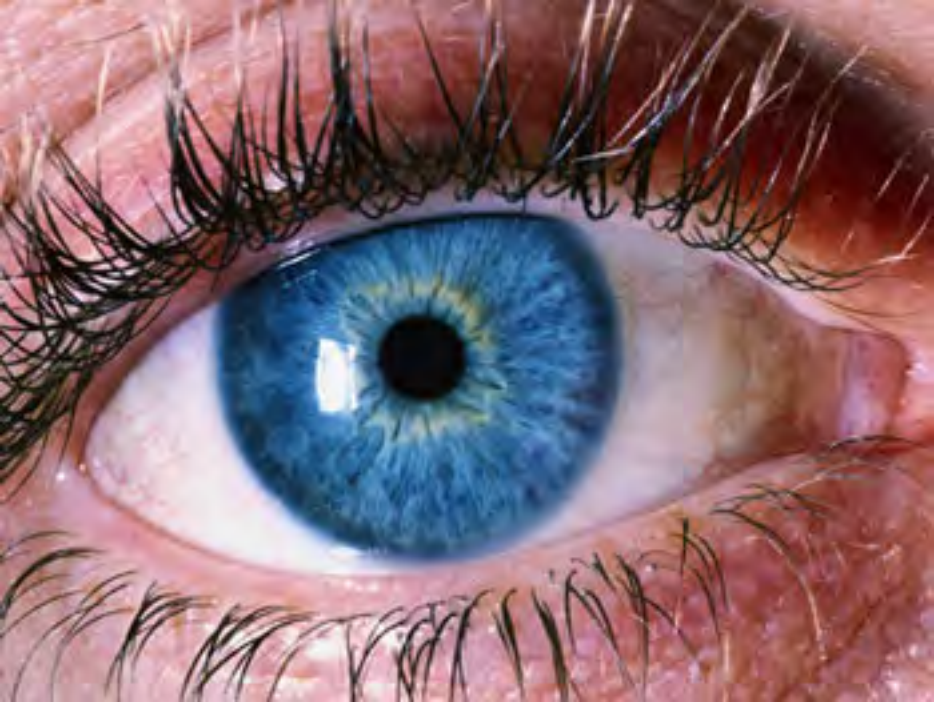IRIDODOLOGY

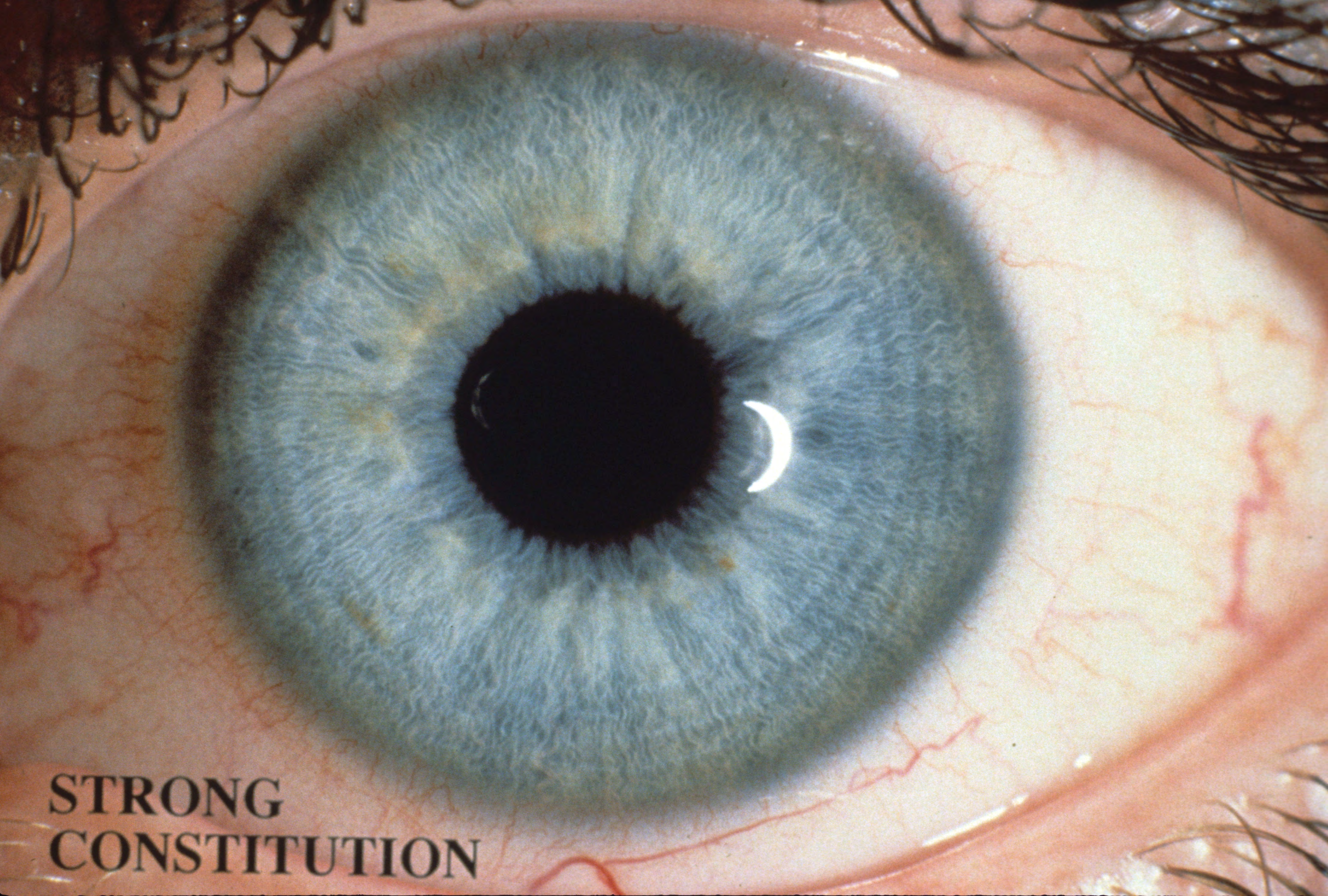
body

mind

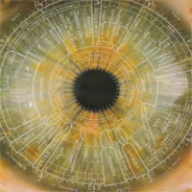spirit

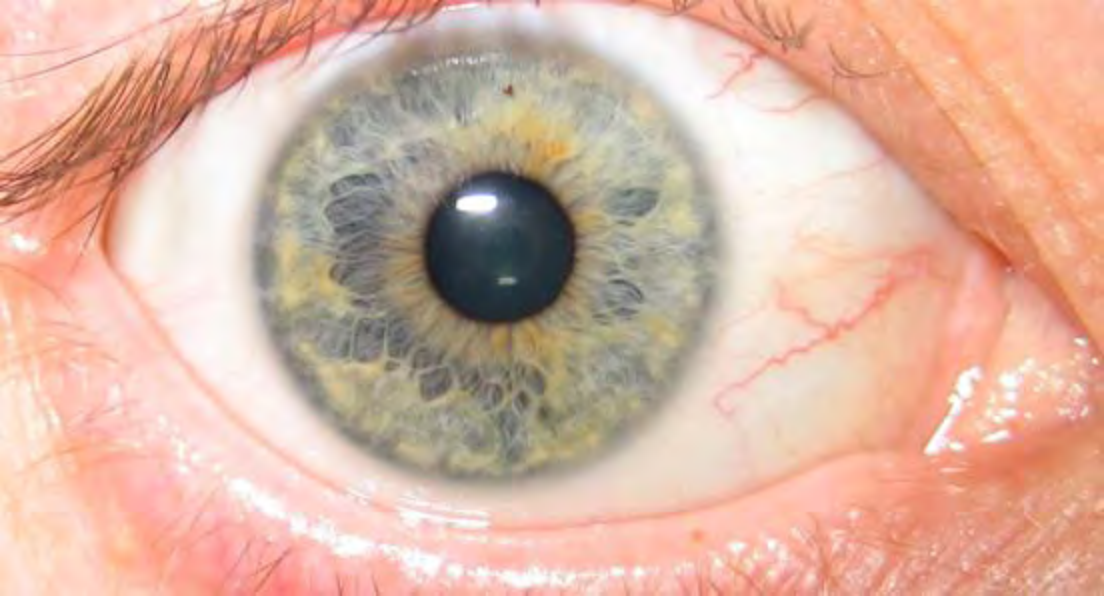


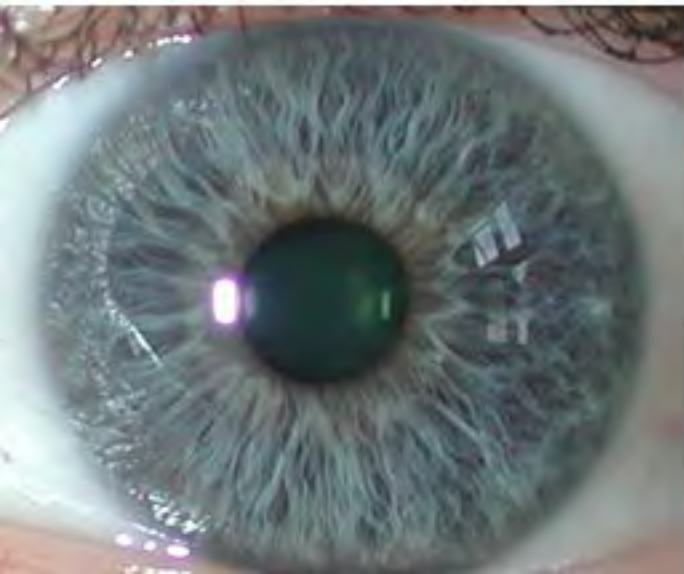
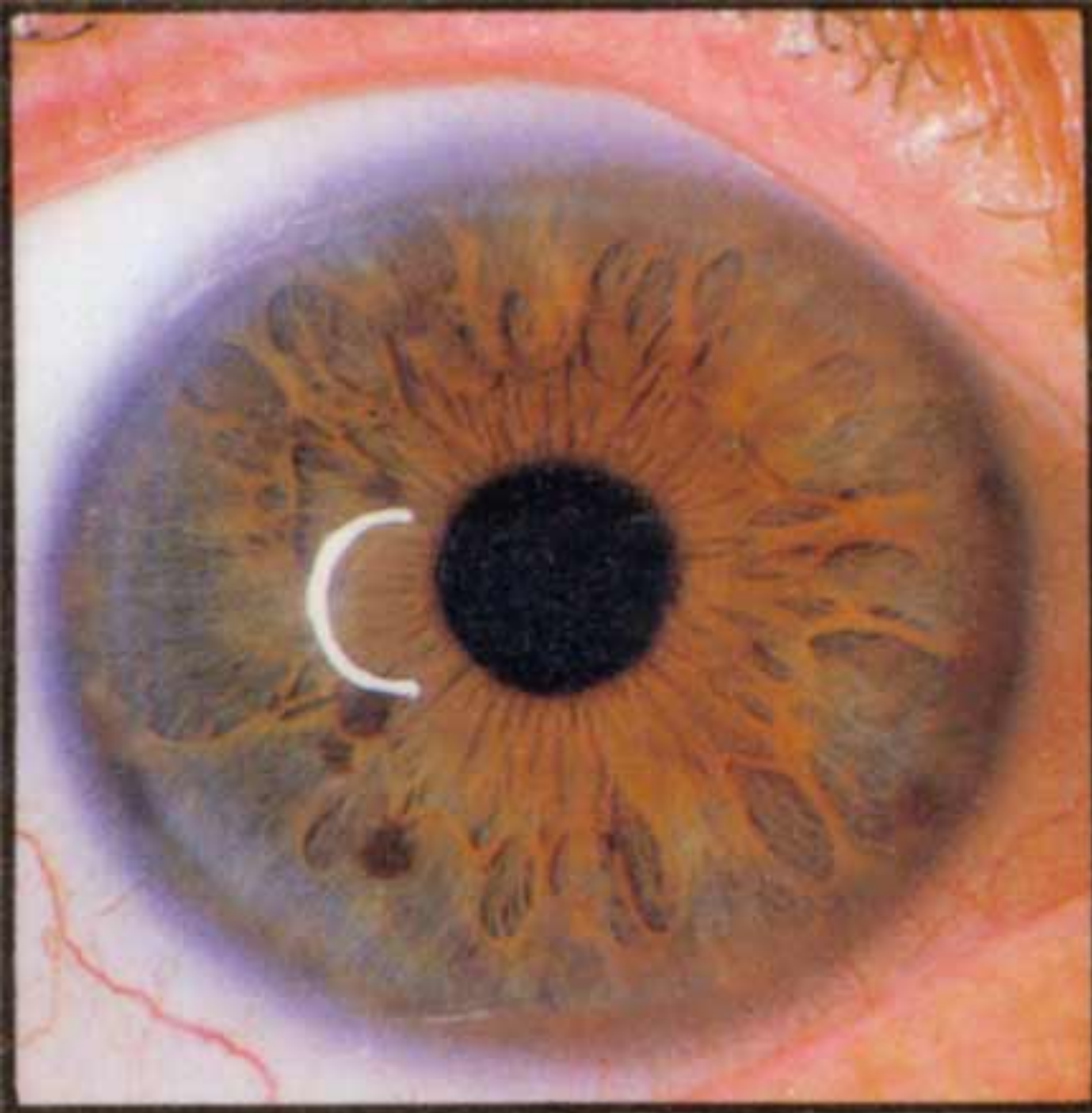


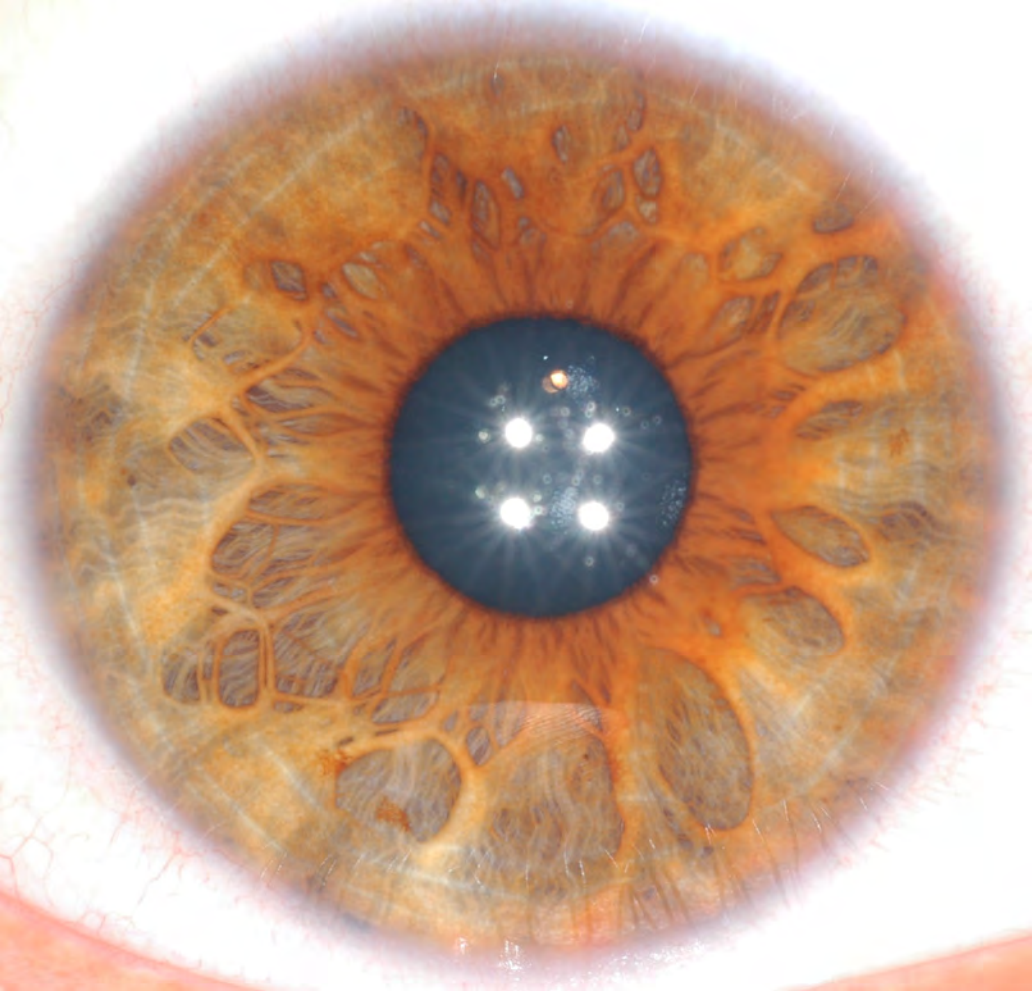
**STRONG
CONSTITUTION**

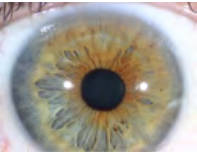

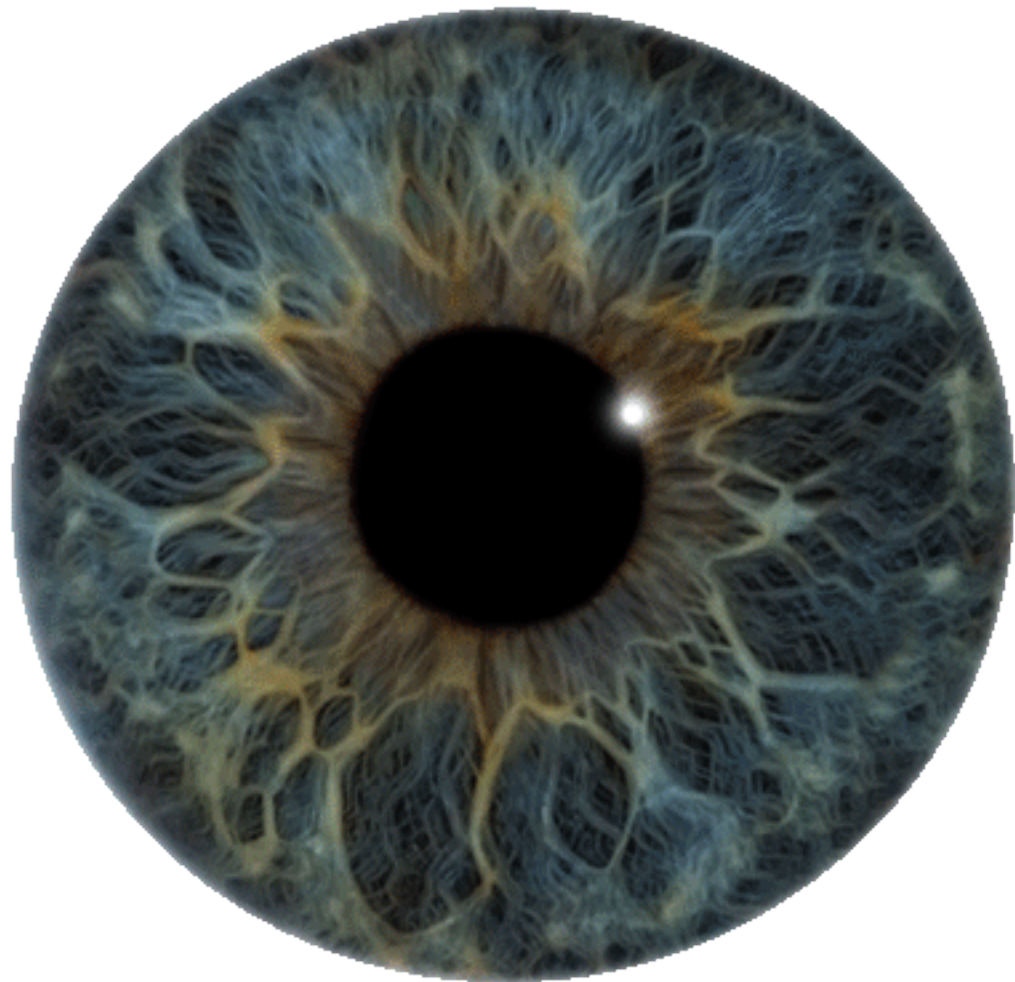
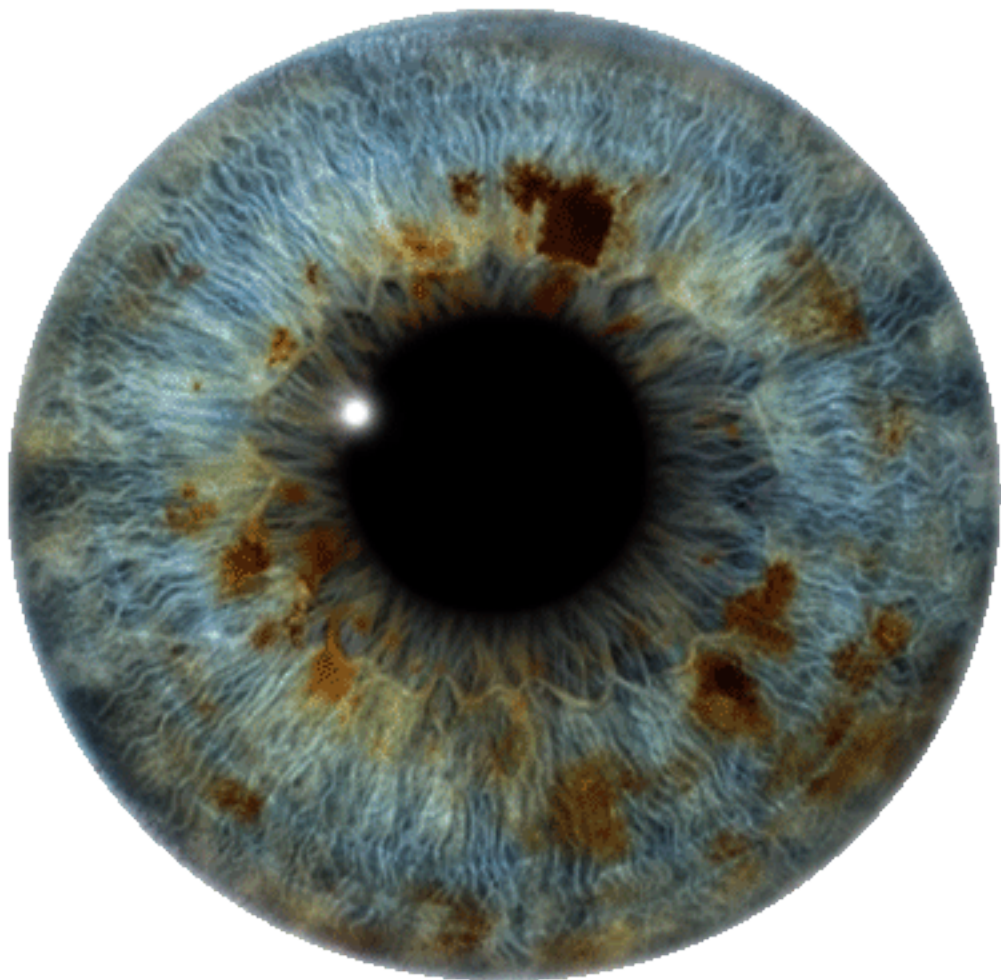



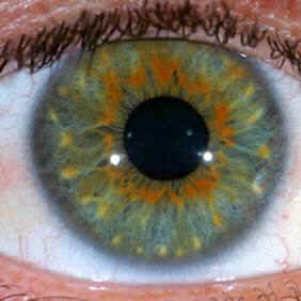






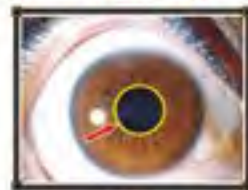



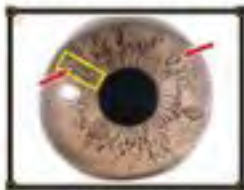十二大症狀

TWELVE RIS SYMPTOMS



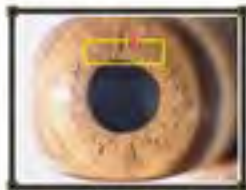
胃環

STOMACH RING



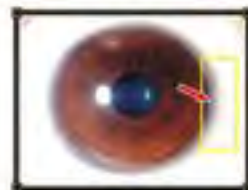腸道與憩室

THE COLON & DIVERTICULEM



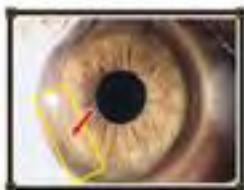橫結腸下墜

PROLAPSUS



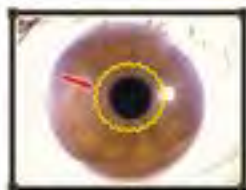膽環

SODIUM CHOLESTERY RING



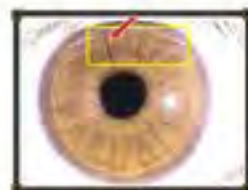神經緊張環

NERVE RINGS



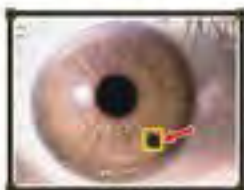自主神經環

AUTONOMIC NERVE WEATH



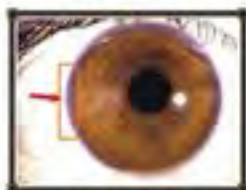
陽光放射環

RADIIS SOLARIS



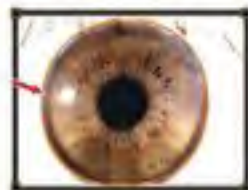色素沉澱斑

HYPER PIGMENTATION



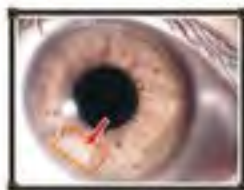靜脈充血環

VEINIS CONGESTION



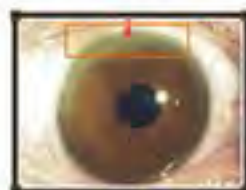皮膚代謝環

SCURF RIM



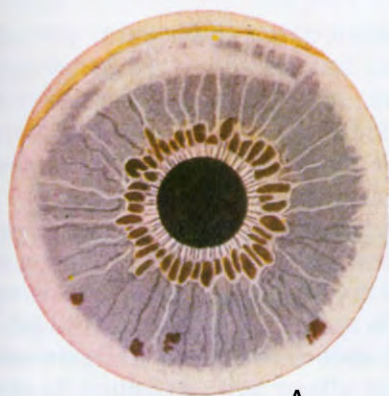淋巴玫瑰環

LYMPHATIC ROSARY

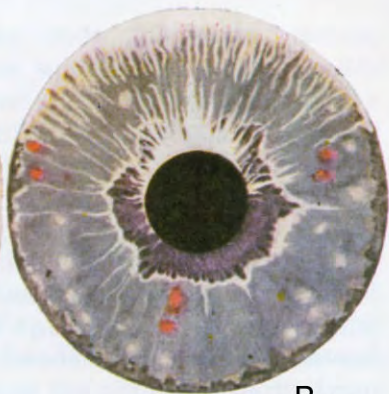


老化環

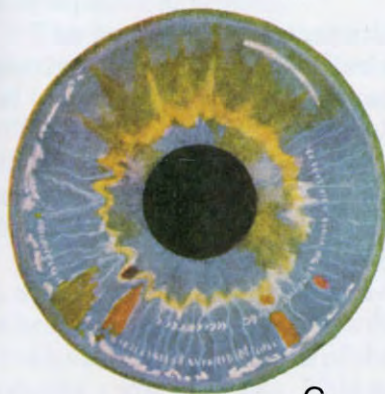
ARCUS SENILIS



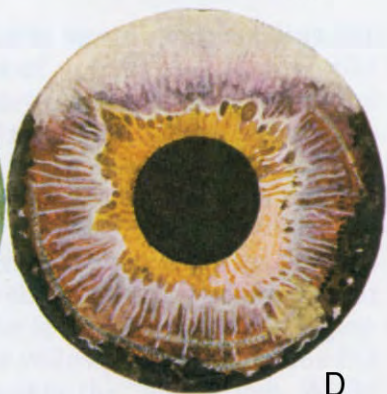A



B



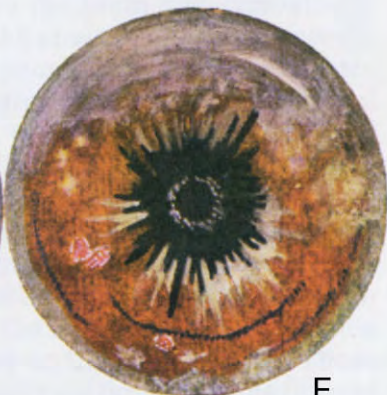C



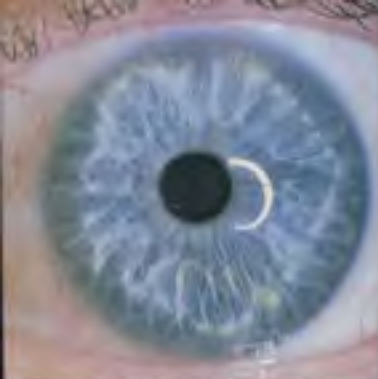D



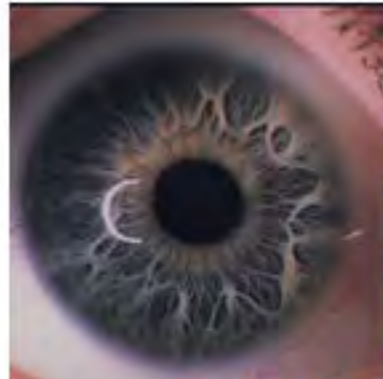
E



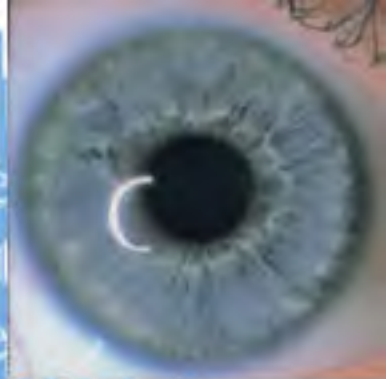F



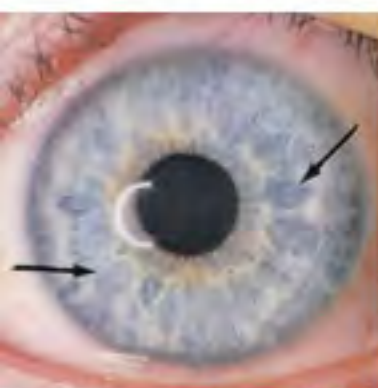Acute Inflammation



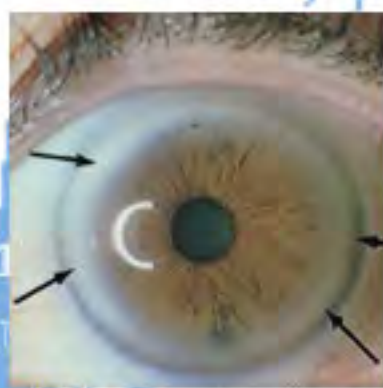
Bowel Spasticity



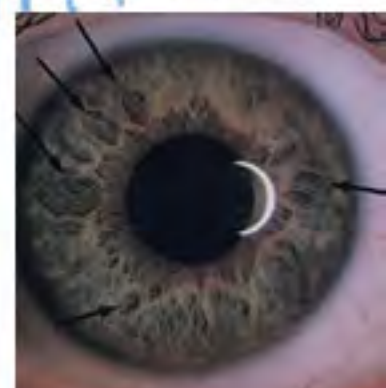
Bowel Stricture



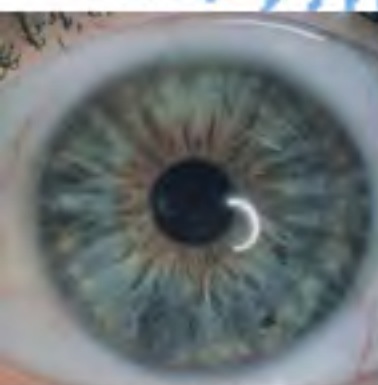Catarrhal Eye



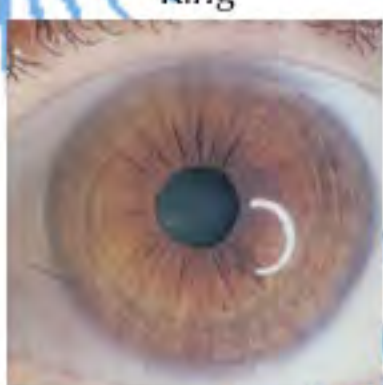Cholesterol Sodium Ring



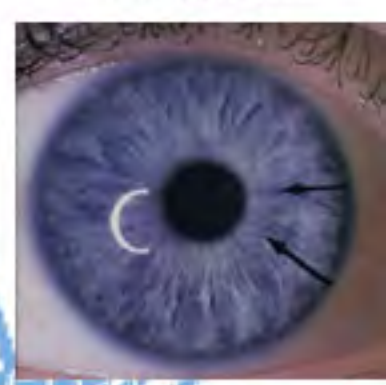Healing Lines



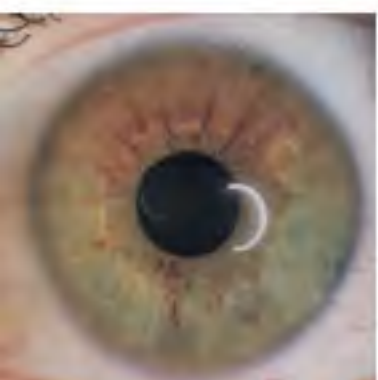Lymphatic Rosary



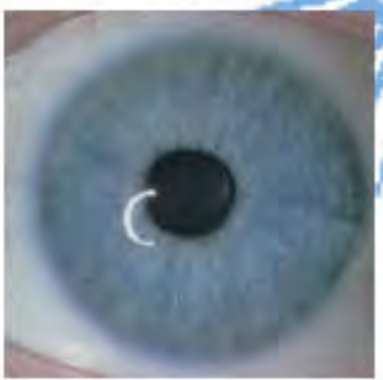Nerve Rings



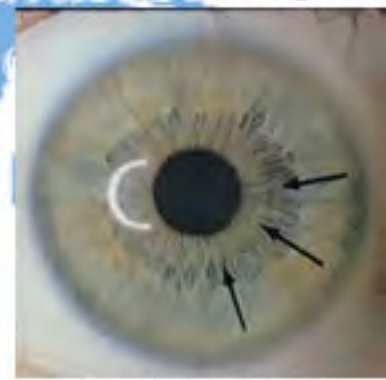Over Acidic Stomach Ring



Sinus Congestion



Strong Constitution



Under Acidic Stomach Ring



Open Lashes



Good Lashes



Heavy Cornea



Red Cornea



Lymphatic & pre-artery Cornea



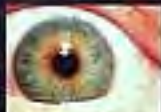Disrupted Cornea



Wide Circle



Narrow Circle



Round Circle



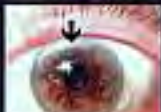Down Circle



Small Half Zone



Large Half Zone



Open Nostril



Chamber Ring



Lymphatic Nostril



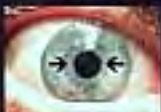Red Nostril



Teary Nostril



Darkening of the C Flap Border



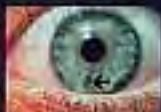Downward Flap



Upward Flap



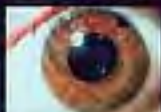Chamber Flap



Regenerative Flap



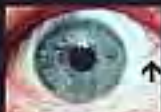Melanin



Mydriasis



Pupil Flaring



Melanin Vessel



Purplish Vessel



Pinkish Vessel



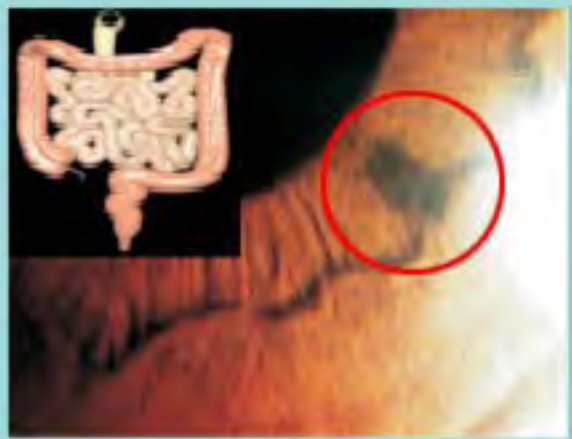Spiral Vessel

FUNDAMENTAL IRIDOLGY SIGNS

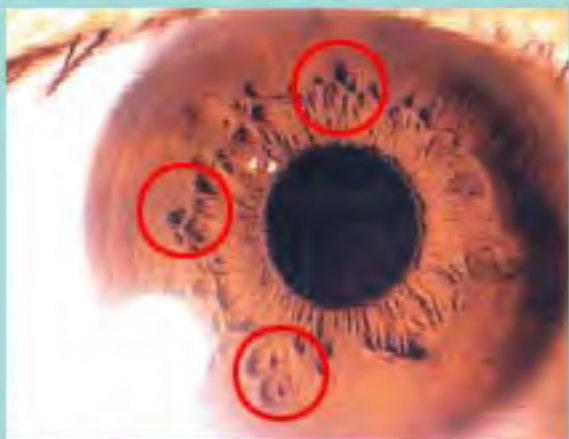© 2000 by the International Association of Iridology



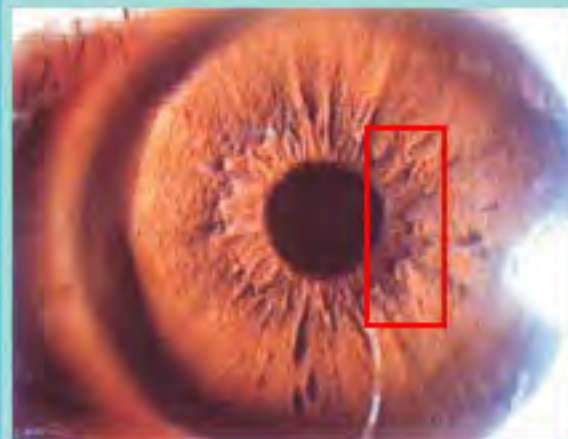INTERNATIONAL ASSOCIATION OF IRIDOLGY
10000 W. 10th Avenue, Suite 100, Golden, CO 80401



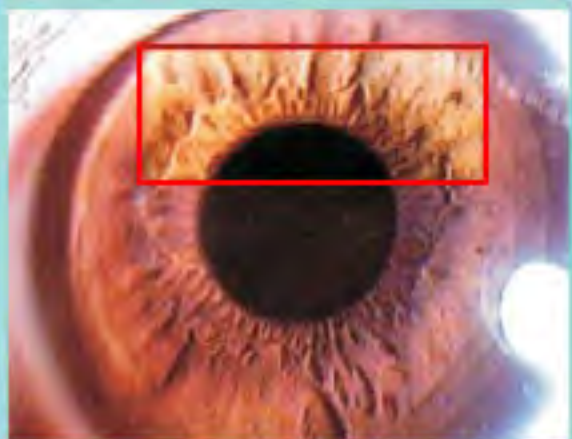腸環惡性黑斑



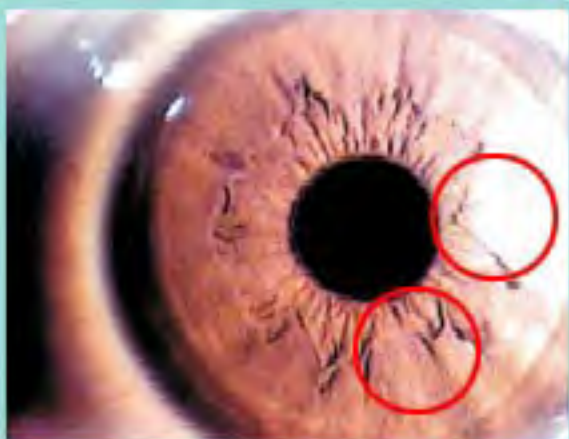結腸憩室-瘰肉



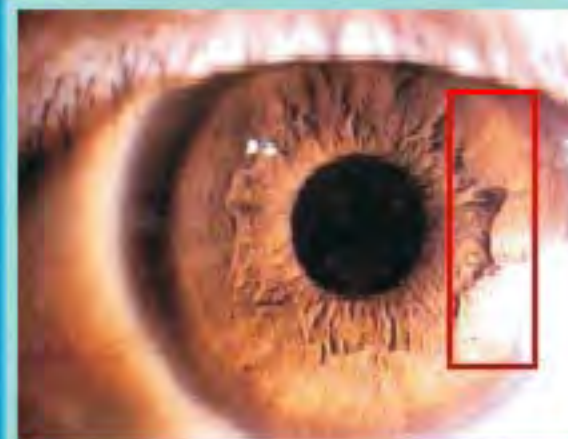結腸腸道狹窄



橫結腸下墜



結腸肌痙攣



結腸氣因性膨脹